

See discussions, stats, and author profiles for this publication at: <https://www.researchgate.net/publication/334679885>


Keratoconus– A Refractive Surgery

Article in Delhi Journal Of Ophthalmology · September 2016
DOI: 10.7869/djo.195

CITATIONS
0

READS
18

2 authors, including:



Parth Patel

Armed Forces Medical College

7 PUBLICATIONS 0 CITATIONS

SEE PROFILE

Some of the authors of this publication are also working on these related projects:



Premium IOL's- Making them Work [View project](#)

Keratoconus - A Refractive Surgery !

Arun C Gulani, Parth G Patel

DOI: <http://dx.doi.org/10.7869/djo.195>



Arun C Gulani

Keratoconus refractively speaking, is a genetically driven corneal shape anomaly with a spectrum ranging from Keratoconus, to Keratoglobus and Pellucid Marginal degeneration. With a prevalence beyond quoted figures with newer and more sensitive diagnostics, it is important that we diagnose this visually debilitating condition early and then determine how to improve vision as a long term goal in these patient populations.

To approach this condition as a vision procedure and even label it as a refractive surgery is a mindset that we propose towards an un-conditioned commitment to making these patients see and see without glasses or contact lenses in most cases to lead a productive life.

We need to first understand the fundamental optics and planning variables associated with the disorder. The term Keratoconus is derived from the Greek words Kerato (cornea) and Konos (cone). It is a condition where the cornea is shaped like a rugby ball instead of a basketball and is the most common primary ectasia. Corneal thinning normally occurs along with corneal protrusion causing high myopia and irregular astigmatism, drastically affecting visual quality (Figure 1). There has been a recent increase in its incidence due to improved diagnostic techniques with estimates between 5 and 23 per 10,000.¹⁻³ There have been various modalities of treatment tried for keratoconus but the disorder still incites fear in the hearts of ophthalmologists who tend to associate it with bad visual outcomes.

Majority of the treatments aim to halt the progression of the disease (Intacs, corneal cross linking) and preserve the vision at its present state. Modalities to improve vision like specialty contact lenses are useful but have their limitations. But, in today's world of increased patient awareness and demand, merely stopping the progression of the disease or executing surgical acrobatics is not enough. If the eye has

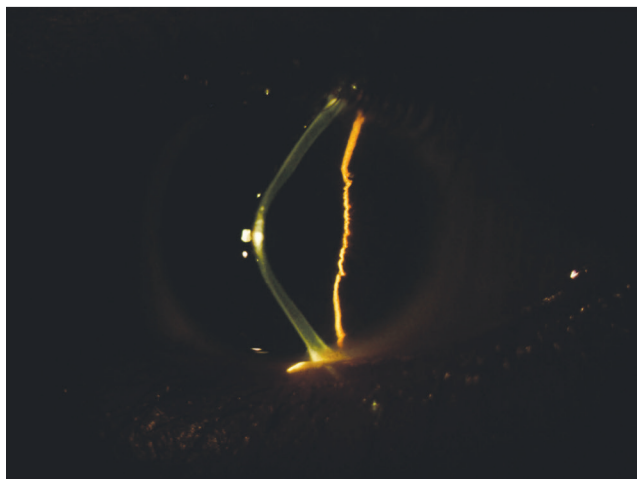


Figure 1: Slit lamp biomicroscope photo showing keratoconus

the potential to see, then it is the surgeon's job to retain or improve that visual acuity regardless of how complex the starting point may be. As long as there is no ongoing disease or irreversible blindness, every eye deserves unaided emmetropia. All ocular surgeries should provide the patient with the best vision possible and thus it is time that we treat keratoconus surgery as a refractive surgery.

The concept of using brief, topical, aesthetically pleasing, and visually promising techniques singly or in combination is what I have introduced as a super specialty called corneoplastique.⁴ Corneoplastique involves all types of LASIK, cataract, and corneal surgery to manipulate the optical elements of the eye and result in a final emmetropic outcome. These principles of Corneoplastique are of prime importance if we wish to make this transition from non-precise to precise refractive surgeries in the treatment of keratoconus. We should approach keratoconus as a refractive disorder (ie, myopia and/or astigmatism) with associated anomalies of a thin cornea, decentered apex, and a possible scar. The backbone of this thought process and surgical planning is based on the "5S" system - sight, site, scar, strength, and shape.

The Gulani 5 S system (Sight, Shape, Scar, Site and Strength) is a simple classification that directs the logical flow of thoughts that one needs to achieve the best vision possible in a patient while following all the principles of corneoplastique.⁵

Each of these categories act as milestone in our brain, which directs our direction of planning and management.

1. **Sight:** Does the patient have potential sight? A 'YES' to this question means that we HAVE to do something for this patient. It puts the responsibility of having to perform to bring the patient to his best potential vision, on us.
2. **Shape:** Corneo-refractive surgery depends primarily on the corneal shape. Most laser procedures reshape the cornea to achieve vision. Every cornea can be grouped as either 'Regular cornea' or 'Irregular cornea'. Regular cornea includes refractive errors like myopia, hyperopia and astigmatism whereas irregular cornea encompasses irregular astigmatism and ectatic conditions like keratoconus, keratoglobus or lasik ectasias.
3. **Scar:** A corneal scar plays an important role in determining the vision. Thus we should actively look for any scars in the cornea. If present, we should determine its depth and site.
4. **Site:** Whether the scar is 'central' or 'peripheral'. A central scar would guide us that it needs to be addressed in this patient.

5. **Strength:** The cornea can be structurally normal or abnormal. An abnormal cornea could be thin (ectasias) or thick (Fuch's dystrophy). These structural deficiencies need to be addressed by either a DSAEK (in fuch's) or Intacs/LK (in ectasias). (Figure 2)

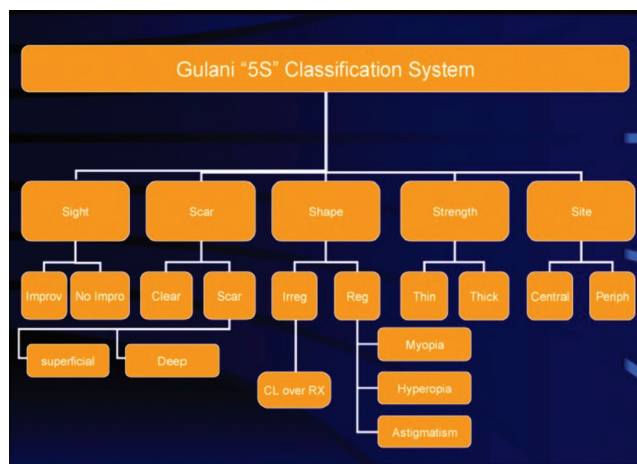


Figure 2: Gulani "5S" classification system

For example, a male patient has a corneal thickness of 450 μm and a documented cone on topography. In terms of the 5S system, we should make sure that he has the potential to see (sight [visual acuity]). The patient has sight, there is no scar, and the site (center or periphery) is not affected. Moreover, the patient has a relatively thin cornea (strength) and a high amount of astigmatism (shape). In terms of the 5S system, we must therefore correct for sight and shape. Once we know which aspects of the 5 S need correction, we can easily choose from the various treatment options we have. Spectacles can be used only in cases of early keratoconus. As the disease progresses, the irregular astigmatism makes it difficult to achieve good vision with spectacles.² Contact lenses are useful in early to moderate cases of keratoconus. Although contact lenses for keratoconus are manufactured with gas permeable and hybrid (i.e., rigid centre and soft skirt) materials, The high levels of irregular astigmatism cannot normally be corrected with hydrogel, silicone hydrogel contact lenses and thus gas permeable contact lenses are most commonly used.⁶ Contact lenses provide good vision and control keratoconus progression, but are associated with increased corneal scarring.⁷ Recently, Hybrid contact lenses, such as SoftPerm (Ciba Vision, Duluth, Georgia, USA), and Synergeyes (SynergEyes, Carlsbad, CA, USA) have shown relative success.^{8,9} Penetrating keratoplasty (PK) has been for long the 'go to' treatment for advanced cases. In a 7 years follow-up study of 2363 keratoconus subjects, 21.6% required PKP.¹⁰ Unfortunately, even in this era of refractive surgery, many surgeons resort to PK for cases of keratoconus without considering other lesser invasive and more precise options. In our opinion, PK should be only used a last resort in extremely complicated cases of keratoconus. Thus, the failure of conventional vision improving modalities (spectacles, contact lenses) and highly invasive surgical options (which greatly reduce

visual outcomes), stress the need to find alternative, precise and more predictable treatment options to get good visual outcomes in keratoconus. In today's era of premium diagnostics and surgical technologies, it is imperative that we treat keratoconus as a refractive surgery, aiming for pristine vision, rather than 'damage control' measures. Treating keratoconus as a refractive surgery opens up numerous treatment options for us like intacs, corneal crosslinking, lamellar corneal procedures, Advanced surface ablation, lens based strategies and combination surgeries.

Intra Corneal Rings Segments (INTACS)

Which was originally developed for low myopia, has become an extremely valuable treatment option for keratoconic patients.^{11,12} The implantation of one or two polymethyl methacrylate segments in the corneal stroma to reshape its abnormal shape, not only improves vision but also increases contact lens tolerance. Intacs have also shown a decrease in higher order corneal aberrations, especially coma.¹³ If the patient in the above example had a thin cornea and a BCVA of less than 20/40, we would choose to implant Intacs. We should educate the patient that Intacs are not mathematically predictable, but we know that he will be moving in the right direction. Intacs can be performed in various forms (single, paired, and steep axis), by various methods (intralase or manual) and in various thicknesses and sizes to customize each shape effectively (Figure 3). We can also perform advanced laser surface ablation over the Intacs to treat residual astigmatism (Figure 4). Even in cases where a predictable visual end-point is not possible, intacs help us to make the cornea more stable (increase corneal strength by acting as 'braces') and measurable. This converts the cornea into a vision- rehabilitation platform which can then be manipulated towards Best Potential Vision.

Corneal Cross-Linking (CXL)

Increases corneal rigidity and biomechanical stability. The procedure includes riboflavin (0.1%) solution application and corneal radiation with ultraviolet-A (370 nm). Ultraviolet- A light radiation activates riboflavin generating reactive oxygen species that induce covalent bonds between collagen fibrils thereby improving corneal strength, best corrected visual acuity and a reduction in cone progression.¹⁴ This technique can also be used in combination with other methods like intacs, surface ablation

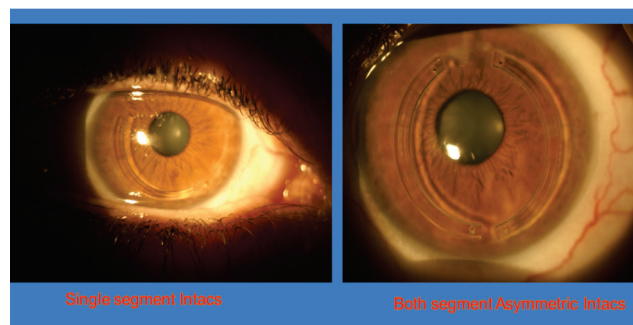


Figure 3: Slit Lamp Image showing single and both segments of INTACS in keratoconus

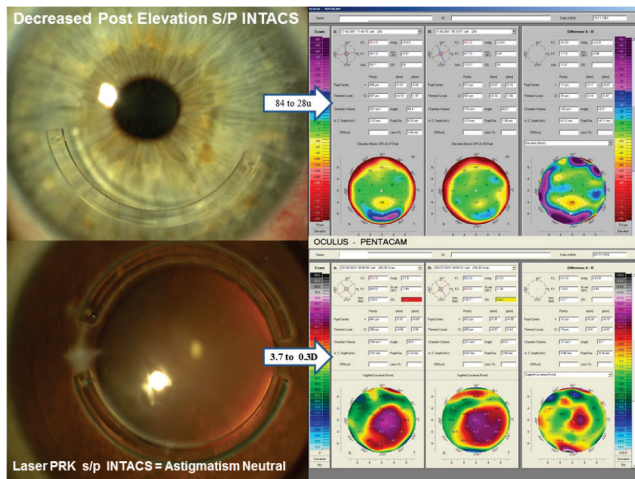


Figure 4: Laser surface ablation resulting in decrease in residual astigmatism post INTACS

and lens based surgeries to make the refractive outcomes more 'permanent'. CXL can be done before or after the other procedures. We have encountered cases of both the scenarios, and feel it is better if the procedure is done AFTER other vision enhancing procedures. It is like 'putting cement on the scoliotic spine only after straightening it'. Performing CXL before the corneal shaping procedures halts the cornea in the abnormal state without improving the vision. PiXL (Photorefractive Intrastromal CXL) allows Customisable, differential CXL application to specific corneal areas which induces predictable refractive changes.^{15,16} It radically increases the use of CXL not just for stabilising, but also as a refractive surgery by reshaping the cornea.

Continuing with the above example, we would perform advanced laser surface ablation in the patients with a cornea which has adequate strength and no scar but requires shape modification for achieving vision. Astigmatic treatments remove the least amount of tissue. Use of excimer laser to remedy anterior corneal pathology and to reduce the steepness of the cone is not a new concept. While such treatments for conditions reducing BCVA in patients is commonly 'accepted', an elective use of the excimer technology to improve Unaided vision is lesser explored. Newer methods like topography-guided surface ablation have been shown to reduce corneal irregularity and thus refractive error. From a medico-legal standpoint, we would explain to the patient that, with this technique, we should be able to reshape his cornea to provide predictable vision. We would inform the patient that we have Intacs (Addition Technology, Des Plaines, IL) as a backup option if his keratoconus progresses. We have devised a set of criteria for laser PRK surgery for keratoconus which is useful for surgical planning and prognosis determination.

Gulani - Nordan criteria for laser PRK in keratoconus:¹⁷

1. Patient is symptomatic with poor visual acuity, double vision, or glare and cannot tolerate contact lenses. Options of glasses or contact lenses are limited and/or unsuccessful.

2. Clinical examination and signs suggesting corneal shape irregularities characteristic of keratoconus.
3. Best corrected visual acuity of 20/30 or better (even if with hard contact lens trial). Best corrected vision below 20/40 would indicate Intacs.
4. Refraction is stable with review of prior documented exams.
5. Astigmatism higher than myopia is preferred.
6. Corneal thickness is more than 400 microns at the thinnest point. Calculation of treatment plans determines the thinnest point should not be less than 350 microns post-operatively.
7. Corneal scar, if present is less than the anterior one-third stroma in depth.
8. Patient understanding - a) using an excimer laser in patients with keratoconus is an off-label procedure, b) if due to laser treatment or natural progression, their ectasia worsens, they would be candidates for other corrective procedures, such as Intacs, lamellar keratoplasty, or penetrating keratoplasty.

What if the same patient has a scar? Using the 5S system, we would need to clear the scar, add strength, and correct the shape of this patient's cornea (he has sight). Thus, a variety of lamellar corneal transplantation techniques can address these affected "S" systems. Six months to 1 year postoperatively, we can perform advanced laser surface ablation for the refractive error (correcting shape) and aim for an emmetropic outcome for this patient (Figure 5).

In many cases, high myopia could be the main culprit along with astigmatism. Depending on the patient's age, he or she may be a candidate for a lens based procedure. Phakic implants (eg, the implantable contact lens) or a toric IOL (if patient also has cataract) are an excellent option. In pseudophakic patients, piggyback IOLs can help correct the residual error (Figure 6).

More importantly, we can combine techniques, such as Intacs with cataract surgery, a phakic implantable contact lens with Intacs, or a lamellar transplant with laser surgery, a piggyback IOL with laser ASA or even multiple procedures like intacs + cataract + laser ASA (Figure 7).¹⁸ All the corneal

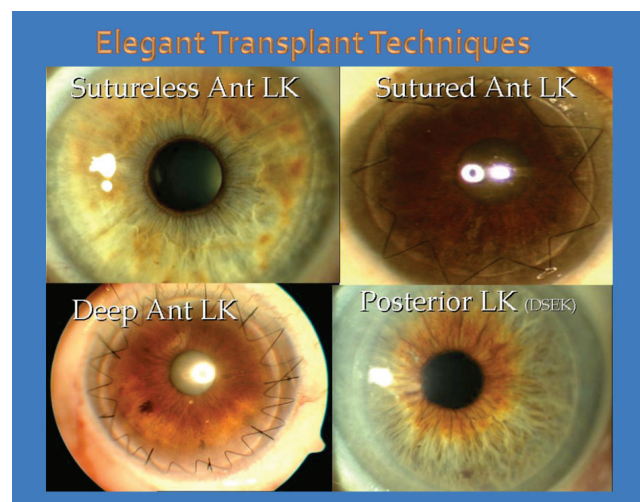


Figure 5: Lamellar corneal transplant options in Keratoconus cases with scar

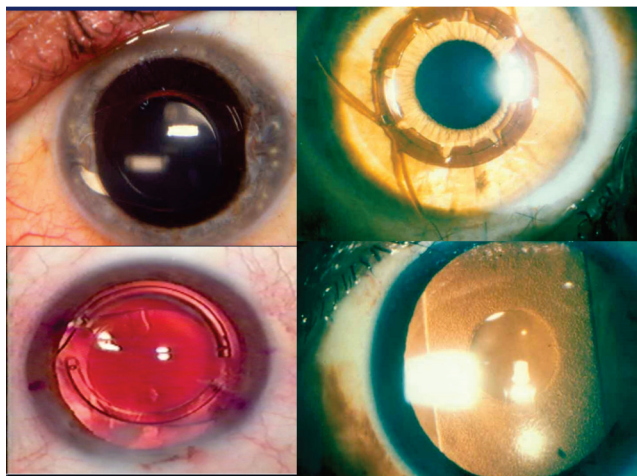


Figure 6: Various lens based options for treating high myopia with astigmatism in keratoconus

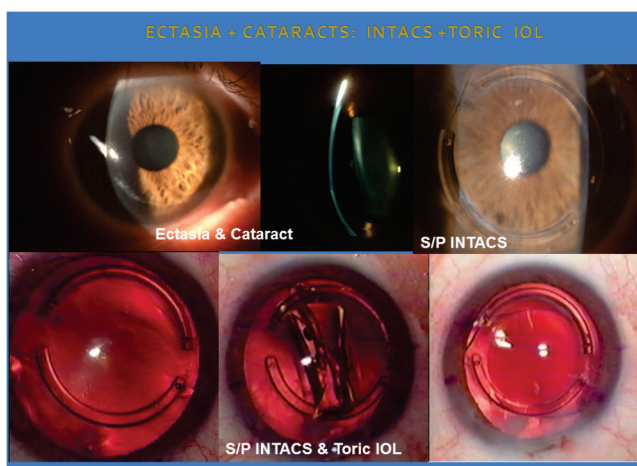


Figure 7: Representative case showing serial insertion of INTACS followed by Toric IOL for management of refractive error in a patient of keratoconus

procedures can be followed by a CXL procedure if required. The options for designing a vision treatment plan for each case of keratoconus are limitless. Thus we can see how keratoconus can easily be approached in a logical manner and corrected with precision like every other refractive surgery. We urge colleagues to avoid taking 'knee jerk' decisions and resist penetrating keratoplasty in keratoconus patients as far as possible. Every treatment must be a customized endeavor with individualized goals aiming for perfect vision. This will transform our outlook in approaching keratoconus patients from a stressful " what to do " to " how can I design this patient's vision."

Cite This Article as: Gulani AC, Patel PG. Keratoconus - A Refractive Surgery. *Delhi J Ophthalmol* 2016;27;5-8.

Acknowledgements: None

Date of Submission: 26/04/2016 **Date of Acceptance:** 31/05/2016

Conflict of interest: None declared

Source of Funding: Nil

References

- Kennedy RH, Bourne WM, Dyer JA. A 48-year clinical and epidemiologic study of keratoconus. *Am J Ophthalmol* 1986; 101:267-73.
- Rabinowitz YS. Keratoconus. *Surv Ophthalmol* 1998; 42:297-319.
- Krachmer JH, Feder RS, Belin MW. Keratoconus and related non-inflammatory corneal thinning disorders. *Surv Ophthalmol* 1984; 28:293-322.
- Gulani AC. Corneoplastique™: Art of LASIK & cataract surgery. *Ind J Ophthalmol* 2014; 62:3-11.
- Gulani AC. Gulani 5S Classification System. In: Sachdev MS, ed. *Tips & Tricks in LASIK Surgery*. Kent, UK: Anshan Ltd; 2007; pp. 91-100.
- Lim N, Vogt U. Characteristics and functional outcomes of 130 patients with keratoconus attending a specialist contact lens clinic. *Eye* 2002; 16:54-9.
- McMonnies CW. Keratoconus fittings: apical clearance or apical support?. *Eye Contact Lens* 2004; 30:147-55.
- Rubinstein MP, Sud S. The use of hybrid lenses in management of the irregular cornea. *Contact Lens Anterior Eye* 1999; 22:87-90.
- Piskalns B, Fink BA, Hill RM. Oxygen demands with hybrid contact lenses. *Optom Vis Sci* 2007; 84:334-42.
- Tuft SJ, Moodaley LC, Gregory WM, Davison CR, Buckley RJ. Prognostic factors for the progression of keratoconus. *Ophthalmology* 1994; 101:439-47.
- Nosé W, Neves RA, Burris TE, Schanzlin DJ, Belfort Júnior R. Intrastromal corneal ring: 12-month sighted myopic eyes. *J Refract Surg* 1996; 12:20-8.
- Colin J, Cochener B, Savary G, Malet F. Correcting keratoconus with intracorneal rings. *J Cataract Refract Surg* 2000; 26:1117-22.
- Shabayek MH, Alió JL. Intrastromal corneal ring segment implantation by femtosecond laser for keratoconus correction. *Ophthalmology* 2007; 114:1643-52.
- Raiskup-Wolf F, Hoyer A, Spoerl E, Pillunat LE. Collagen crosslinking with riboflavin and ultraviolet-A light in keratoconus: long-term results. *J Cataract Refract Surg* 2008; 34:796-801.
- Kanellopoulos AJ. Novel myopic refractive correction with transepithelial very high-fluence collagen cross-linking applied in a customized pattern: early clinical results of a feasibility study. *Clin Ophthalmol* 2014; 8:697-702.
- Jacob S. Photorefractive Intrastromal CXL (PiXL). Eurotimes Stories, 2015. Available from: <http://www.eurotimes.org/node/1876>
- Gulani AC, Nordan LT, Alpíns N, Stamatelatos. Excimer Laser Photorefractive Keratectomy for Keratoconus. In: Wang M, editor. *Keratoconus & Keratoectasia: Prevention, Diagnosis, and Treatment*. Thorofare NJ: Slack Inc; 2010. p. 145-151.
- Gulani AC. Think Outside the Cone: Raising Keratoconus Surgery to an Art. *Advanced Ocular Care*, Nov 2010. p. 35-37. Available from: <http://eyetubeod.com/2010/12/think-outside-the-cone-raising-keratoconus-surgery-to-an-art>

Author Affiliation:

Arun C Gulani MD, MS

Former Chief of Cornea & Refractive Surgery University of Florida
Director and Chief, Gulani Vision Institute in Jacksonville, Florida-USA
Email: gulanivision@gulani.com