

Sutureless Amniotic Surgery for Pterygium: Cosmetic Outcomes for Ocular Surface Surgery

Arun C. Gulani, MD

Gulani Vision Institute

Jacksonville, FL

Pterygium is one of the oldest pathologies known to ophthalmologists. Surgery for this condition can range from simple excision to techniques with exotic detail and meticulous maneuvers with task-specific instruments beckoning an era of raised expectations and cosmetic outcomes in the field of ocular surface surgery itself.

In my previous publications, I had emphasized on complete removal along with amniotic grafting as a key concept for success.^{1,2}

The part of the pterygium that is visible is only the tip of the iceberg (iceberg concept). By removing only this visible portion, the main pathology with its tentacles is not addressed and remains hidden under the conjunctiva.

Theories about the etiology of pterygia are diverse and range from hereditary, neurotrophic, angioplastic, and immunologic causes to ultraviolet light exposure. Regardless of the cause, the result is elastotic degeneration with vesiculation of Bowman's membrane in the cornea and formation of epithelial islets (Fuchs patches) as cysts around the pterygium (seen as glove-finger appearance on histopathologic study).

Anatomically, the pterygium is composed of several segments, including Fuchs patches and Stocker line (the iron line), the hood, the head, the body, and the superior and inferior edges.

Having previously classified pterygia into 4 categories, I have continuously studied the presentations and the outcomes in improving the surgical approach and outcomes over the years to add an additional way to classify the pterygium based on the adhesion of the head to the ocular surface and vascularity along with the draw test on the cornea.

Pterygia can therefore have the following:

Head/neck adhesion. Peripheral or central adhesion.

In cases of peripheral adhesion, the pterygium easily peels off the cornea.

Vascularity. Engorged, tortuous vessels and simultaneous conjunctival fold contracture signifies a more aggressive pterygium. This same concept can be used to determine outcomes postoperatively.

Draw test. On tugging on the cornea, some pterygia may be small but outright gritty and deep into the cornea resulting in thin cornea when removed. Preparation for this before surgery helps plan a smooth outcome (amniotic graft itself can be used as a lamellar fill). Also, removal of these pterygia is more difficult from the corneal surface.

Amniotic membrane. The advantages of the commercially available membrane are that there is no immune reaction, and it has anti-inflammatory functions, is antiadhesive and antibacterial, encourages epithelial differentiation and growth, and has an antitissue growth factor effect.

Amniotic membrane has been used as a surgical material since the 1940s, and the membrane has been shown to have a strong antiadhesive effect.^{3,4} Amniotic membrane has a thick collagen layer and an overlying basement membrane with a single layer of epithelium. The use of amniotic membranes has been suggested as a replacement for a function substrate as the presence of normal substrate is essential for normal proliferation and differentiation of epithelial cells. This is also true in the cornea because the corneal epithelium and the underlying stromal cells have been shown to interact intimately through various cytokines. Kim and Tseng⁵ used preserved human amniotic membrane to supply a normal substrate in rabbit chemical burn models, and they were able to successfully reconstruct the ocular surface. In the present series, we have used amniotic membrane, the innermost layer of the fetal membrane, for the treatment of pterygium wherein after the removal of proliferative tissue, amniotic membrane was placed on the sclera and adhered to the sclera with glue.

In my surgical approach, I still use the following criteria and treat the pterygium as if it were a corneal scar (remember, with every surgery, I plan for unaided 20/20) and wish for surgery to leave the vision untouched.

Thus, the basis of my surgical steps involves a lamellar approach along with atraumatic pterygium removal as a

Address correspondence and reprint requests to Arun C. Gulani, MD, Gulani Vision Institute, 8075 Gate Pkwy (W), Suite 102, Jacksonville, FL 32216 (arungulani@aol.com).

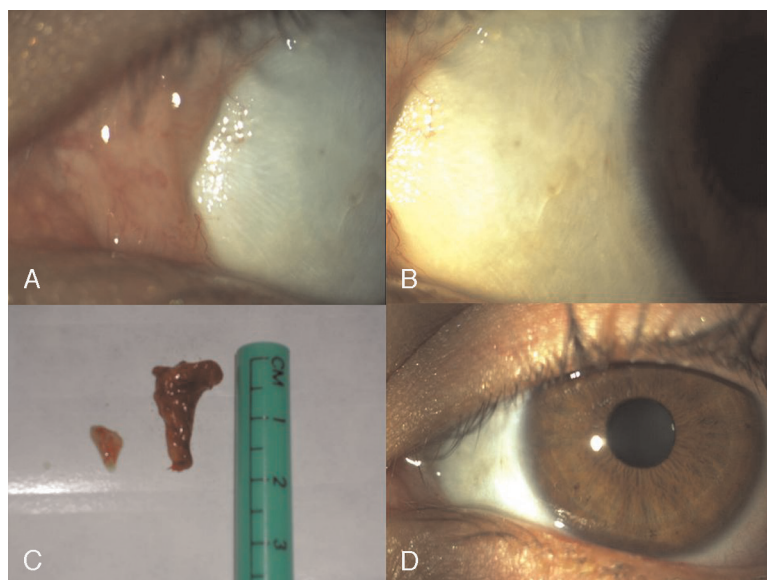


FIGURE 1. A and B, High magnification images of the glued amniotic membrane for pterygium. C, Iceberg concept. The pterygium visibly removed during pterygium surgery and the real amount of pterygium that actually needs to be removed. D, One-day postoperative with makeup on lids.

conjunctival scar with full dissection right up to the roots, including all arising heads followed by subconjunctival mitomycin-C application and amniotic graft layering on the sclera with glue.

The following are the criteria for surgical plan:

- extent of the pterygium;
- density of the pterygium;
- involvement of adjacent structures;
- draw test;
- head/neck adhesion; and
- vascularity.

■ TECHNIQUE

Topical anesthesia in the form TetraVisc (Ocusoft/Cynacon, Richmond, Tex) is applied with preoperative topical Vigamox (Alcon, Fort Worth, Tex). Intralesional anesthesia in the form of lidocaine with epinephrine is used 1 to 2 mL (this can also delineate the extent of the pterygium in obscure cases).

At the start of the procedure, the head of the pterygium is lifted off the cornea. This can be done with posterior-to-anterior sweep using the Gulani pterygium cross-action spreader. In cases of mild adhesions, the pterygium can be easily pushed off the cornea with a Weck cell sponge or effectively peeled in a single centrifugal movement.

After smoothing the cornea with a specially designed blunt blade, remnant tissue (especially in gritty kind of pterygium) is meticulously removed with toothed forceps and blade used again to smooth the limbus. A

Weck cell sponge (Medtronic Xomed Inc, Jacksonville, Fla) soaked in epinephrine is used during this time tucked away into the nasal crevice where the cut pterygium is pressured into hemostasis. (In this way, by the time this step is done, we approach a bloodless field again for dissection.) Topical epinephrine is used to create vascular hemostasis.

The most important stage is dissecting the pterygium. The whole plane of the pterygium is delineated subconjunctivally. When it is removed, it resembles a spreading mass of tentacles. It is important to remove the entire mass to avoid recurrence.

The pterygium is dissected carefully superiorly to avoid buttonholing the conjunctiva and invading the orbital septum and inferiorly to avoid cutting the underlying muscles, which is rechecked after the pterygium is removed.

There is none to very minimal bleeding during surgery. (The cautery is to be used only for cosmetic reasons.)

Weck cell sponge pieces are soaked in mitomycin-C 0.04% and placed under the conjunctiva (rolled over these pieces) in the area of the dissection and left in place for 30 seconds. After removing the sponges, the area is flushed with copious balanced salt solution.

I use the cornea as an illuminated receiving table to drape the amniotic membrane, which is then placed on the raw area and draped with a tyre-tool technique (to avoid touching the membrane with any instrument) so it slips under the surrounding cut edge of the conjunctiva medially, superiorly, and inferiorly.

This is then milked to adhere to the globe contour using a specially designed forceps.

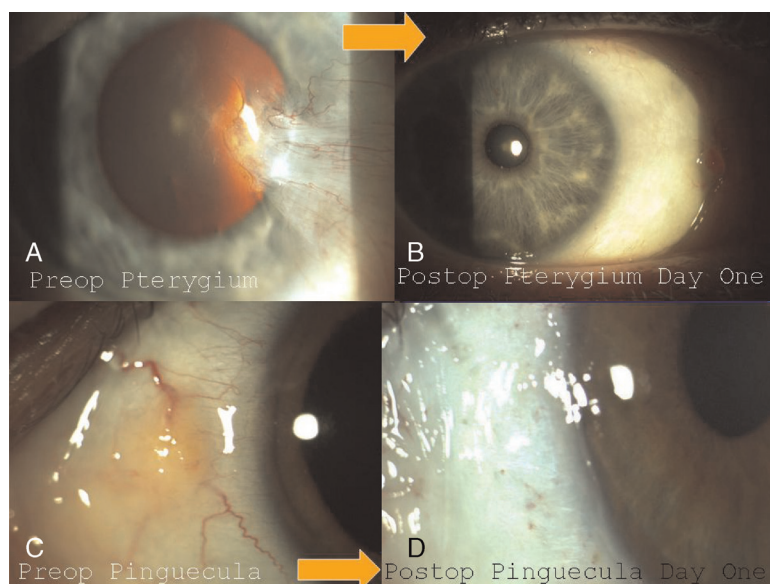


FIGURE 2. A, Preoperative pterygium. B, One-day postoperative pterygium. C, Pinguecula preoperative. D, One-day postoperative pinguecula.

Tisseel glue (Baxter US, Deerfield, Ill) is now applied under the membrane, and the membrane is milked again in 2 quick sweeps.

Check the fornices for excessive glue and clear with a forceps sweep. Too much glue may cause irritation and keratitis the next day if left behind.

In Recurrent Pterygia

The surgery is exactly the same no matter how aggressive and recurrent the pterygium is. The bleeding is again very minimal if you follow this pearl.

Select an area which is more amenable to approach and dissect down into this area until you reach the scleral bed. (Most usually, the previous ophthalmologist must have done a meticulous job of clearing the sclera.) Once you reach sclera, dissect from behind forwards, and the whole pterygium mass will lift up in a form I call "armor technique" (very much like a thick plate of armor).

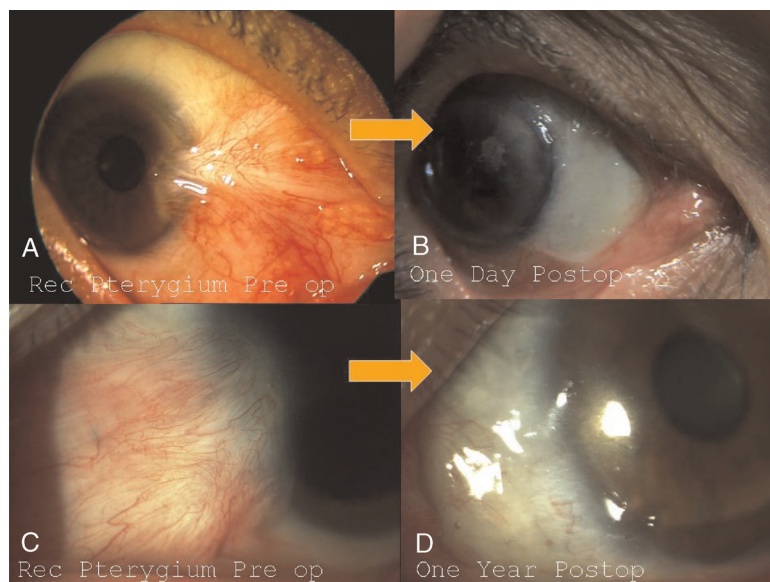


FIGURE 3. Recurrent pterygium outcomes. A and B, Recurrent preoperative and one-day postoperative. C and D, Recurrent preoperative and one-year postoperative.

Once again, bleeding will be minimal. (People try to cut and vigorously dissect. That will lead to bleeding and losing the plane of easy dissection.)

In my practice, which has a pterygium referral base from practically all over the world, patients are made to walk up to a mirror the next day (1 day postoperative) to appreciate that their eye looks like it has had no surgery. You can see that many of the type A personalities will even wear makeup the next day.

The cosmetic appeal of the outcome with the no stitch, no patch, and no red approach along with absence of visual deficit is raising the bar in patients now seeking this approach for related ocular surface conditions.⁶⁻¹⁰ Additionally, these patients can also avail of laser vision surgery and/or cataract surgery very soon in succession because the cornea is basically cleared (for photorefractive keratectomy) with excellent globe contour (for suction ring during laser-assisted in situ keratomileusis) and for temporal/superior incision during cataract surgery.¹¹

Pterygium surgery has led itself to an increase in the requests for pinguecula removal for patients in whom their appearance may be troubling to the patient or threatens their livelihood (movie stars, models, etc).

Here again, because the bar has been raised on outcomes, pinguecula removal follows the same principle as pterygium surgery.

Ocular surface surgeries have reached a status of cosmetic outcomes and will lead into improving many borderline cases for ocular surface suitability for laser vision correction, thus becoming an integral part of every refractive surgery practice.^{12,13}

■ ACKNOWLEDGMENTS

The author wishes to acknowledge Prachi Nandoskar, M.D., Fellow in Advanced LASIK and Corneoplastique Surgery at Gulani Vision Institute for documenting outcomes and data collection as medical monitor for this study.

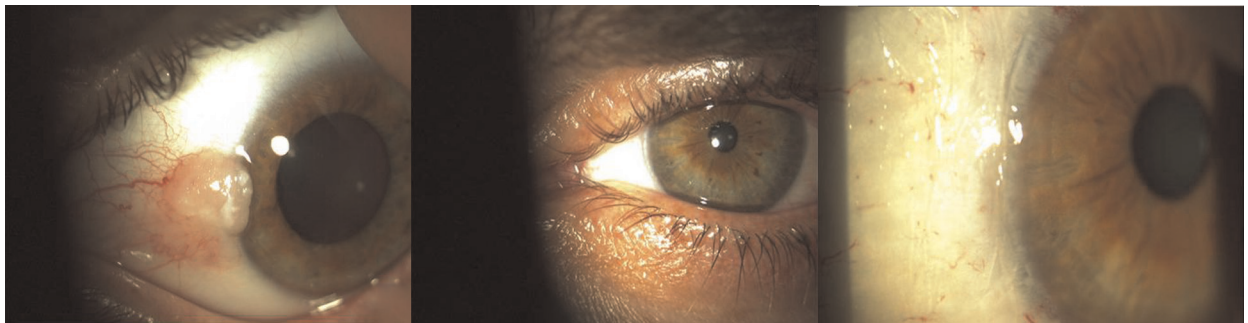


FIGURE 4

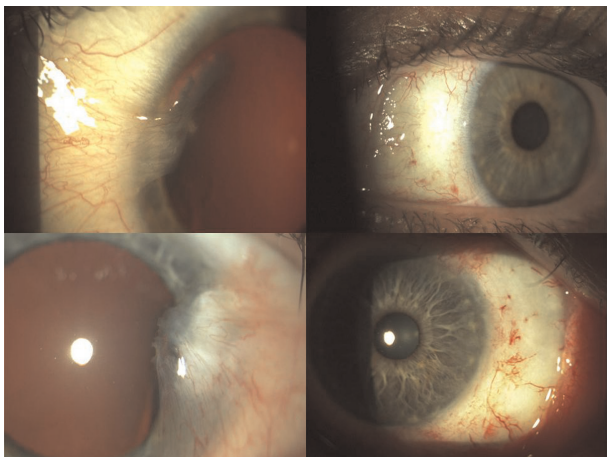


FIGURE 5

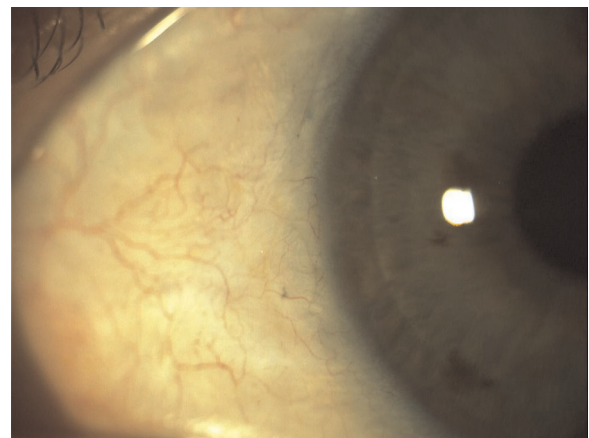


FIGURE 6

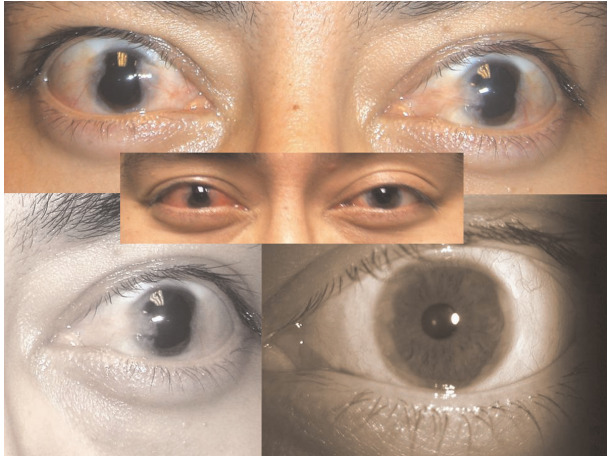


FIGURE 7

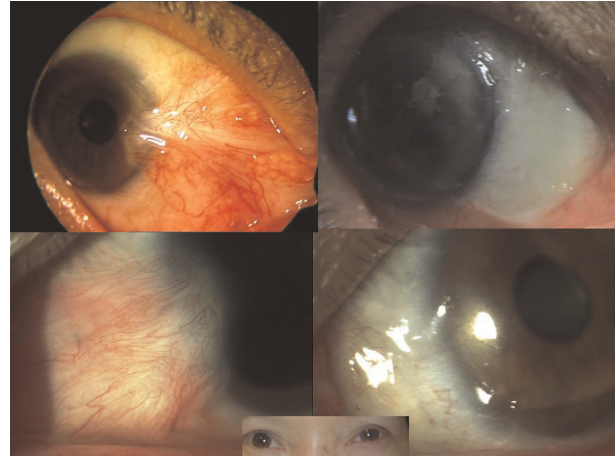


FIGURE 8

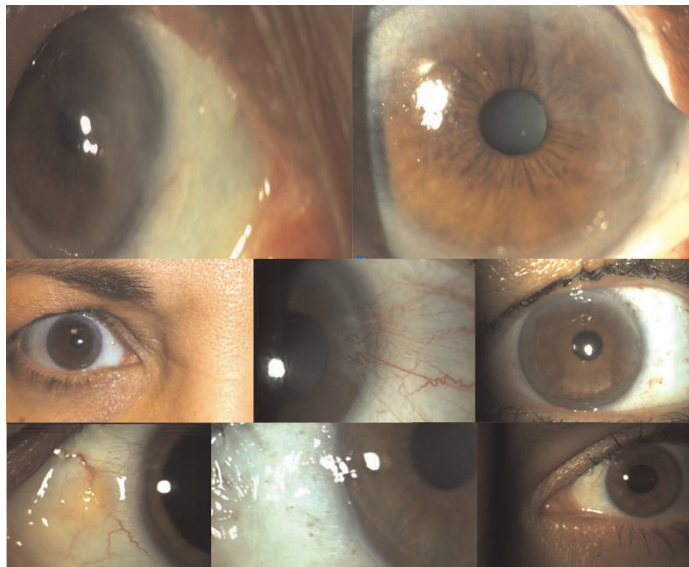


FIGURE 9

REFERENCES

1. Gulani A, Dastur YK. Simultaneous pterygium and cataract surgery. *J Postgrad Med.* 1995;41:8–11.
2. Gulani AC. Amniotic membrane lowers chance of pterygium recurrence. *Ophthalmol Times.* September 15, 2003.
3. Trelford JD, Trelford-Sauder M. The amnion in surgery, past and present. *Am J Obstet Gynecol.* 1979;134:833–845.
4. Tayyar M, Turan R, Ayata D. The use of amniotic membrane plus heparin to prevent postoperative adhesions in the rabbit. *Tokai J Exp Clin Med.* 1993;18:57–60.
5. Kim JC, Tseng SCG. Transplantation of preserved human amniotic membrane for surface reconstruction in severely damaged rabbit corneas. *Cornea.* 1995;14:472–484.
6. Gulani AC. Dry eye matrix. Innovator's lecture. Paper presented at: ASCRS; 2002, Philadelphia.
7. Gulani AC. Corneoplastique™ SASRCS, Durban; August 2005.
8. Gulani AC. Advanced corneal surgery course. Paper presented at: AAO; October 2006; California.
9. Gulani AC. Corneoplastique. *Tech Ophthalmol.* 2007;5: 11–20.
10. Gulani AC. Corneoplastique. *Video J Cataract Refract Surg.* 2006;XXII.
11. Gulani AC. A new concept for refractive surgery. *Ophthalmol Manage.* 2006;10:57–63.
12. Gulani AC. Vision corrective surgeries: past techniques, present trends and future technologies. *Northeast Fla Med.* 2007;2:41–44.
13. Gulani AC. *Irregular Astigmatism: Management in Unstable Corneas.* Thorofare, NJ: Slack Inc; 2007;28:51–61.