

ACADEMY

NEWS

Annual Meeting

Published onsite, American Academy of Ophthalmology 1997 Annual Meeting, San Francisco, California. OCT. 27, 1997

GULANI EDGE DELINEATOR AND EDGE LIFTER

BY
ARUN GULANI, M.D.



CURRENT storz® Techniques

Many refractive surgeons involved in performing the LASIK procedure, are also involved in correcting or enhancing previously performed lamellar refractive surgery cases. This new technique can be done at a slit lamp or under the operating microscope. The arc-shaped end of the delineator has a lower edge polished to a sharp finish. The instrument sits snugly in the edge of the previous flap without much epithelial disturbance or wobbling. A simple arc movement delineates the entire edge up to the corneal hinge (Fig 1). The bench-shaped lifter facilitates raising the corneal flap by maneuvering the horizontal plate under the delineated cornea with the vertical plate serving as a rudder. A smooth transition along the delineated arc of the flap causes a uniplanar lamellar separation (Fig. 2). The flap can then be easily lifted with an atraumatic forceps revealing the previous stromal bed (Fig. 3).



Fig. 1

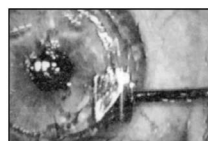


Fig. 2

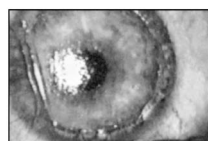
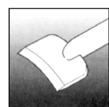
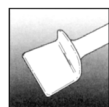
Fig. 3



Delineator



Lifter

E9029 GULANI EDGE DELINEATOR AND LIFTER



For more information call
(800) 325-9505.

storz®



AMERICAN
ACADEMY OF
OPHTHALMOLOGY

Published onsite,
American Academy
of Ophthalmology 1997
Annual Meeting,
San Francisco, California.
Monday, October 27, 1997

GULANI LASIK REVISION TECHNIQUE

BY
ARUN GULANI, M.D.



CURRENT storz® Techniques

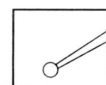


Fig. 1 E9084
Gulani Corneal
Indenter

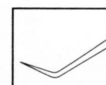

Fig. 2 E9083
Gulani Corneal
Flap Outliner

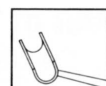

Fig. 3 E9082
Periphery
Dissector

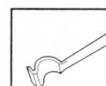

Fig. 4 E9081
Corneal Shovel

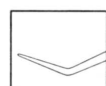


Fig. 5 E9080
Interface
Spatula

The Gulani LASIK Revision Set consists of five instruments designed to fine tune and even correct previous lamellar surgery if necessary. This

is a simple three-step technique for lifting the previous lamellar flap and exposing the underlying stroma for LASIK correction.

The first step utilizes the Corneal Indenter (Fig. 1) to create a light reflex at the original flap edge and the Flap Outliner (Fig. 2) to etch the periphery of the flap.

Next, the Periphery Dissector (Fig. 3) is slipped into the outlined flap so one plate is under the flap and the other above it for uniform peripheral separation of 1.5mm. The peripheral dissection of this amount prepares the flap for complete dissection.

In the final step, the Corneal Shovel (Fig. 4) is used to dissect the flap from the periphery to the hinge. In some cases an irregular interface adherence occurs. The Interface Spatula (Fig. 5) is then used beginning at the point of a dissected edge and is then swept in a single uniplanar motion toward the area of adherence. This relieves the flap in a smooth lamellar dissection with the least damage to the stromal interface.

storz®
OPHTHALMICS

For more information call
(800) 325-9505.

