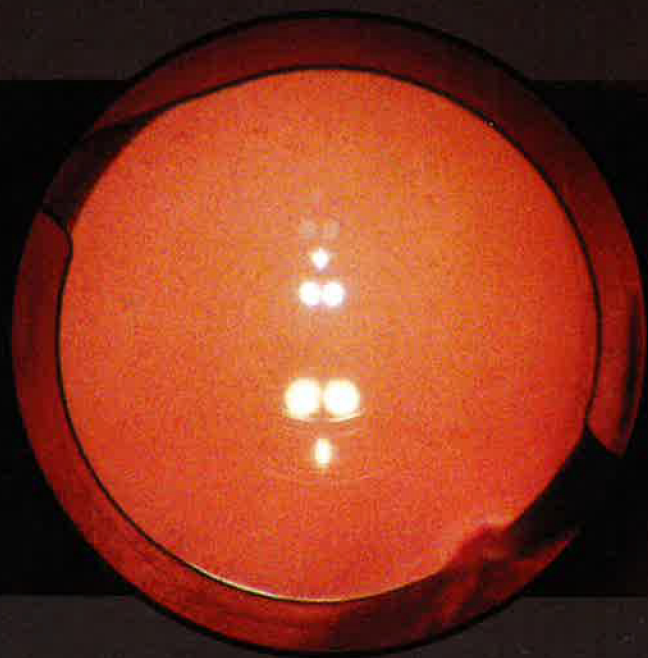

# Refractive Lens Exchange

A Surgical Treatment for Presbyopia

# Femtosecond Laser in Refractive Lens Exchange

*Arun C. Gulani, MD, MS*

Cataract extraction is one of the most frequently performed surgeries in the world, with an estimated 19 million cases performed annually and about 3 million performed in the United States. It is also the safest and most effective surgery with desirable and predictable outcomes. During traditional cataract surgery, the surgeon must access the cataract through small incisions made in the edges of the cornea. Then, the surgeon enters the eye through the incisions, breaks up and removes the cataract, and finally, places and positions an artificial lens in the eye. This has been the preferred method for eye surgeons for extracting the cataract from the front chamber of the eye.

In 2001, a new technology called femtosecond laser technology (FSL) was introduced to ophthalmic surgery as a new tool and technique for refractive surgery. The most commonly known and performed refractive surgery is laser in situ keratomileusis (LASIK).<sup>1,2</sup> As medicine continues to evolve, new techniques are conceptualized and studied to contend with the changes occurring in medicine. The use of the FSL in cataract surgery was first conceptualized in 2005 by researchers D. Palanker and M. Blumenkranz, and was later tested by OptiMedica Corp, a laboratory based in California, in 2005-2010.<sup>1</sup> FSL was first used in a clinical setting in cataract surgery in Hungary in 2008, then by Dr. Steven Slade in the United States in 2010, then in Asia, and finally in Australia in 2011.<sup>1</sup> FSL-assisted cataract surgery possesses the potential to enhance the safety, efficacy, accuracy, and results of cataract surgery; however, it also bears a set of clinical and financial challenges.

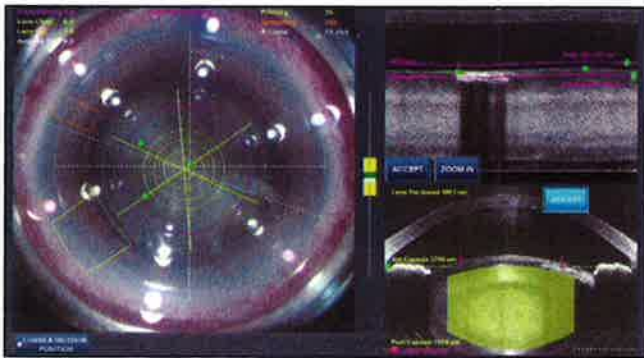
The use of FSL in corneal refractive surgery, such as LASIK, has resulted in favorable outcomes over the years.<sup>2</sup> More recently, it has been applied to cataract surgery. FSL technology is used to assist the eye surgeon with cataract surgery by performing various procedures. FSL technology has the ability to create precise incisions and capsulotomies and assists with the breaking up of the cataract, which is later removed by the surgeon using other technologies.<sup>1,3,4</sup> As of now, the United States Food and Drug Administration (FDA) has approved 4 FSL platforms for assisted cataract surgery (Table 14-1).<sup>5,7</sup>

## CORNEAL INCISIONS

Traditional cataract surgery involves small incisions created manually in the cornea by the surgeon with a sharp blade. Despite the surgeon's expertise and skill, the use of a blade to manually create incisions makes it difficult to control the length and architecture of the incision. Although the rates are very low, the manual incision may later produce adverse effects during the postoperative recovery period. Through studies, it was found that the use of FSL to create corneal and limbus incisions produces consistent and precise results (Figure 14-1). FSL technology has the capability to create incisions in any area of different shapes and at a desired depth and length. Scanning technology obtains three-dimensional (3D) images and scans of the cornea, lens, and the back part of the eye, and the area where the


**TABLE 14-1. COMPARATIVE FEATURES OF FEMTOSECOND LASERS**

LASER PLATFORM	CATALYS	LENSX	LENSAR	VICTUS	ZEIMER
<b>PULSE FREQUENCY</b>	120	50	80	Up to 160	UK
<b>FDA APPROVALS</b>	Corneal/arcuate incisions, anterior capsulotomy, lens fragmentation	Corneal/arcuate incisions, anterior capsulotomy, lens fragmentation, corneal flap	Corneal/arcuate incisions, anterior capsulotomy, lens fragmentation	Corneal/arcuate incisions, anterior capsulotomy, corneal flap	Corneal/arcuate incisions, intracorneal rings/pockets,
<b>CE MARKING</b>	Same as FDA approvals	Same as FDA approvals	Same as FDA approvals	Corneal arcuate incisions, anterior capsulotomy, lens fragmentation, corneal flap	Corneal/arcuate incisions, anterior capsulotomy, lens fragmentation, corneal flap, intrastromal rings/pocket
<b>PATIENT INTERFACE</b>	Liquid optics, nonapplanating, liquid interface, 2-piece, vacuum docking	Softfit, curved lens, applanating, 1-piece, vacuum docking	Robocone, nonapplanating, fluid interface, 2-piece, vacuum docking	Dual modality, curved lens applanating, 2-piece, spherical, solid and liquid, vacuum docking	Liquid optics, vacuum docking
<b>IOP RISE</b>	10.3 mm Hg	16.4 mm Hg	UK	UK	UK
<b>OCULAR SURFACE VISUALIZATION</b>	3D spectral domain optical coherence tomography (OCT), video microscope, and FS laser to enable image-guided cataract surgery	3D spectral domain OCT, video microscope, and FS laser to enable image-guided cataract surgery	3D ray-tracing CSI	3D spectral domain OCT, video microscope and FS laser to enable image-guided cataract surgery	3D Fourier-domain spectral OCT, video microscope and FS laser to enable image-guided cataract surgery

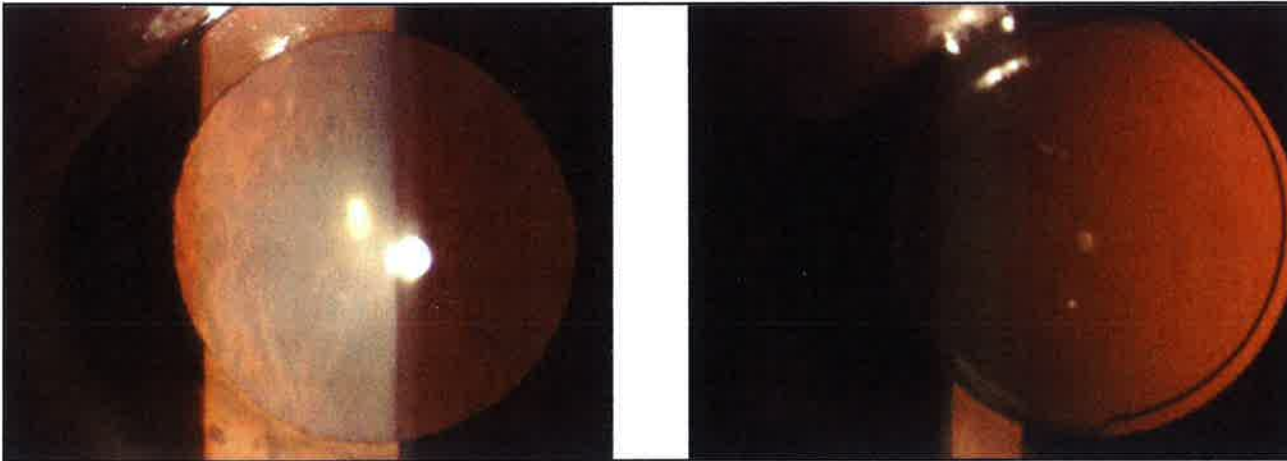


**Figure 14-1.** Femtosecond laser surgical planning display. The corneal incisions are shown on the left side. (Reprinted with permission from Loretta Ng.)

incisions are made is identified. After the area is identified by the technology, the laser creates the incision in about 10 seconds once the surgeon presses the foot pedal.<sup>5</sup> The incision does not actually open the eye, so the surgeon can then enter the eye with a surgical instrument to proceed to the next stage of the surgery. The incisions made by the FSL allow the wounds to close by the normal pressure of the eye, eliminating the need for stitches or surgical sealant glue. Studies have shown that these calculated and precise incisions were also found to reduce the amount of astigmatism created during surgery and improve postoperative uncorrected visual acuity.<sup>5</sup> A clinical study performed in Hungary concluded that the FSL technology reduces the chances of corneal swelling and actually may cause less trauma to the corneal cells compared to the traditional manual procedure.<sup>6-8</sup> The use of FSL in cataract surgery allows the surgeon greater control



**Figure 14-2.** Lens fragmentation using femtosecond laser. (Reprinted with permission from Sondra Black, OD.)



**Figure 14-3.** Femtosecond laser capsulorrhexis in case of pseudoexfoliation.

over surgery and the final refractive endpoint, leading to improved visual outcomes and higher patient satisfaction.

## CAPSULOTOMY

FSL has another feature that is beneficial for cataract surgery. The technology has the ability to create a small, precise circular opening in the front part of the capsule of the lens without damaging the back part of it. Again, clear 3D images of the lens are first obtained, then a specific shape and diameter is calculated and, finally, made in the capsule by the laser. In order to create a near-perfect circular opening while reducing collateral damage, the laser fires in a spiral pattern. Once the laser is done firing, the surgeon removes the tissue with surgical forceps (Figure 14-2). A randomized, controlled study conducted in 2013 evaluated the effectiveness and safety of cataract surgery using FSL vs manual cataract surgery.<sup>9</sup> It was found that the FSL platform was more

effective and safe in cataract surgery and provided precise and reproducible capsulotomies compared to manual procedures.<sup>9</sup> Another study showed improved and greater visual outcomes post-FSL-assisted cataract surgery because of the ability of the technology to create a well-centered opening in the capsule and therefore optimize the surgeon's ability to better implant and position the artificial lens.<sup>4</sup> Finally, FSL-assisted cataract surgery shows a significantly lower internal damage of the eye vs manual procedure.<sup>7,10</sup> The use of FSL in creating capsulotomies during cataract surgery is a great advantage to both surgeon and patient.

## PHACOFRAGMENTATION

*Phacofragmentation* is a medical term used to describe the breaking up of the cataract. The third advantage of FSL technology is its ability to break up the cataract present in the eye (Figure 14-3). This is performed by firing a number

of pulsating shots to the lens in a predetermined and calculated pattern. Once the cataract is broken up, the surgeon then removes the matter using another surgical technology, which, in most cases, is phacoemulsification. The advantages of using FSL for phacofragmentation compared to current methods include reduced average time and energy required to break up and remove the cataract, which has an overall reduced risk of damaging the back part of the capsule. This process makes the overall surgery safer and leads to faster recovery and better visual outcomes.

## COMPLICATIONS

Like any other medical procedure and technique, there are complications and risks with using FSL technology in cataract surgery. Researchers have found that the use of the laser for breaking up denser cataracts may increase the risk of breaking the capsule of the lens because of the increased magnitude needed to break up the cataract. However, this risk may be reduced and even prevented with the surgeon's awareness and careful use of the laser. Another complication discovered by surgeons using FSL is the presence of minor hemorrhages in the white part of the eye. This is caused by the eye-stabilizing unit of the technology, but has been found to not affect the postoperative recovery or vision. Finally, the discovery of new technology and techniques comes with a steep learning curve.<sup>5</sup> In order to be able to safely and effectively use the FSL technology in cataract surgery, eye surgeons must be educated thoroughly and adequately. Although there are complications present with this recently utilized technique, the use of FSL technology in cataract surgery significantly reduces the risks and complications and greatly improves the visual outcomes and satisfaction compared to traditional manual surgery.

## PROCEDURE

The steps required to perform the surgery using one of the four FSL technology platforms are similar, although some steps may vary for each laser platform. To initialize the surgery, the patient's pupil must be dilated and topical anesthesia must be instilled into the operative eye. The patient must remain flat on his or her back with the head secured and tilted to achieve proper application of the laser on the operated eye.

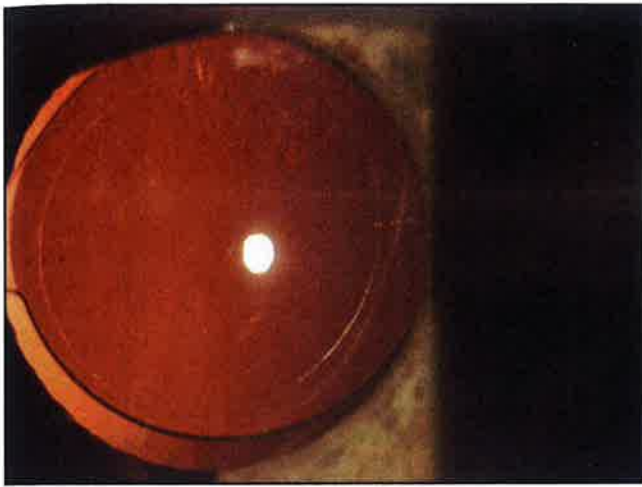
Next, a docking system on the platform is used to stabilize the patient's eye. Depending on which platform is used, there may be contact or noncontact of the cornea with a docking system. The eye is suctioned with a contact lens to stabilize it. Contact with the docking system would require a contact lens placed on the eye to suction the whole eye evenly for proper application of the laser. It is found that the docking system slightly raises the pressure of the eye

(see Table 14-1). The contact docking system may cause corneal folds, which cause incomplete capsulotomies.<sup>5</sup> One of the platforms uses liquid immersion docking, which avoids corneal folds. However, there have been improvements in reducing the chances of corneal folds using the contact-docking interface. A small hemorrhage may occur after the procedure because of the docking of the eye. The hemorrhage usually dissipates a few days postoperatively and does not affect the outcome of the surgery.

After docking is complete, imaging and scanning of the eye are performed. Each of the platforms contains different 3D imaging technology that assists with calculations and surgery. Imaging and scanning of the eye is crucial for the surgeon for several reasons. It is required to find specific areas for incisions and capsulotomy, as well as determining laser pattern mapping. Images of the front and back of the eye are obtained in order to prevent damage to any structures of the eye. Once areas for incisions and capsulotomy are determined and the shape and depth of the incisions are calculated, the laser is activated and the surgeon proceeds.

Once the patient is dilated and anesthetized and docking is complete, the surgeon continues with the laser procedure. FSL technology is used for 3 processes for cataract surgery. The whole laser treatment may last from 30 seconds to 3 minutes, depending on the laser platform being used and the strength of the laser the surgeon selected based on the cataract density. The laser treatment usually begins with creating the opening in the lens capsule, which may last from 1.5 to 18.0 seconds, depending on the laser platform.<sup>5</sup> Next, the surgeon continues to fire the laser with a different laser pattern to break up the cataract in the eye. Finally, the surgeon creates the incisions in the cornea that were predetermined, so that the divided pieces of the cataract can be removed with other technologies. The docking system plays an important role in stabilizing the eye while the laser treatment is in motion. If the suction of the eye is lost and the eye becomes undocked, the capsulotomy must be done manually. The lens break up is done after the small opening is created in the capsule. Depending on the power of the laser the surgeon selected, the lens break up may last from 30 to 60 seconds.<sup>5</sup> Finally, the incisions are made in the cornea or in the periphery of the cornea with a specific length, depth, and shape selected by the surgeon. After the laser treatment is completed, the patient's eye is released from the suction and the patient is slowly undocked. The incisions remain closed and the eye is not opened until the surgeon manually opens the incisions with a surgical tool. The patient's eye continues to remain dilated and the surgeon finally enters the eye through the incisions to remove the matter of the lens and implant an artificial lens.

Having used multiple FSL platforms internationally, I have summarized my acceptance for this technology.<sup>11-16</sup> In cases of refractive lens exchange (RLE) where patients are not suffering loss of best-corrected vision and also may have near-unrealistic expectations of enhanced vision, FSL

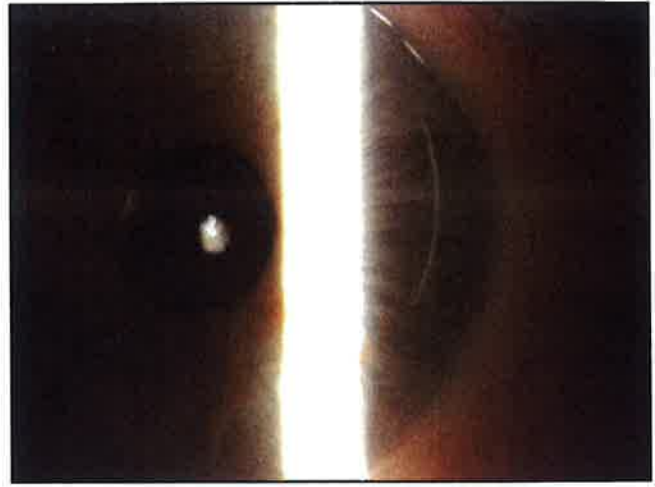


**Figure 14-4.** Femtosecond laser capsulorrhexis in case of subluxed lens.

provides that edge to enhance outcomes and surgical consistency that perhaps even our experienced hands cannot. In certain cases, I would argue that application of FSL could even be a necessity. In cases such as pseudoexfoliation of the capsule (see Figure 14-3), minimally subluxed cataracts (Figure 14-4), and mature cataracts, the capsulorrhexis is the Achilles' heel of the eye surgeon. In these cases, having something as reliable, consistent, and predictable as the FSL reduces complications during the rhexis. In a mature cataract, not only does it set your stage, but it also decompresses the capsular bag to avoid the ominous "Argentinian flag sign."

Lesser indications that could mandate an FSL include cases of anterior corneal dystrophy and Fuch's dystrophy, where the creation of limbal relaxing incisions (LRIs) could abrade the loose epithelium so the patient suffers foreign body sensation the next day, despite a perfect cataract surgery and visual outcome. In these cases, FSL creates the incision intrastromally. The epithelium is, thus, tightly apposed and mostly intact (Figure 14-5). The LRIs are done predictably and can be opened the next day in a controlled fashion.

Given my confidence with this technology, I have extended its use to include cases of previous refractive surgery, refractive complications, associated pathologies, and even combinations to successful emmetropia (Figures 14-6 through 14-8). This wide range of applications, increasing confidence, and technological improvements, along with incorporation of preoperative diagnostics, intraoperative measurements, and combination lenticulo-keratorefractive surgery will bring RLE to a new level of consistent outcomes and safety. This will allow greater adaptation of FSL RLE surgery technology among eye surgeons, as we collectively enter the era of designer vision surgery with multidimensional vision.



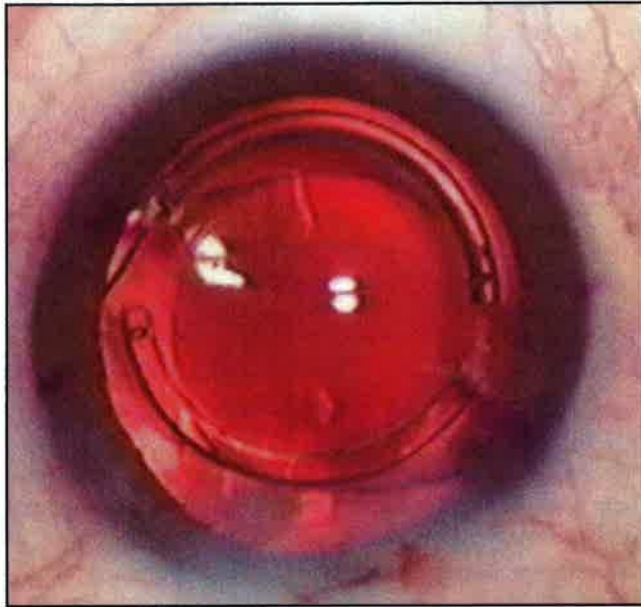
**Figure 14-5.** Femtosecond laser LRI in case of corneal anterior basement membrane disease.

## ACKNOWLEDGMENTS

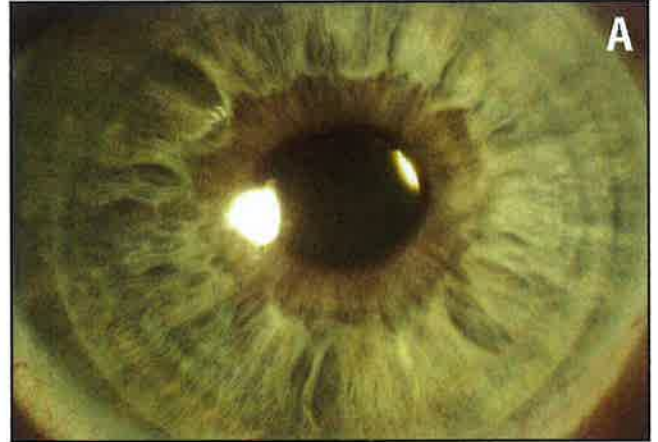
Dr. Arun Gulani would like to acknowledge Preethi Rajan and Khozhiakbar Izakov for their help with this chapter.

## REFERENCES

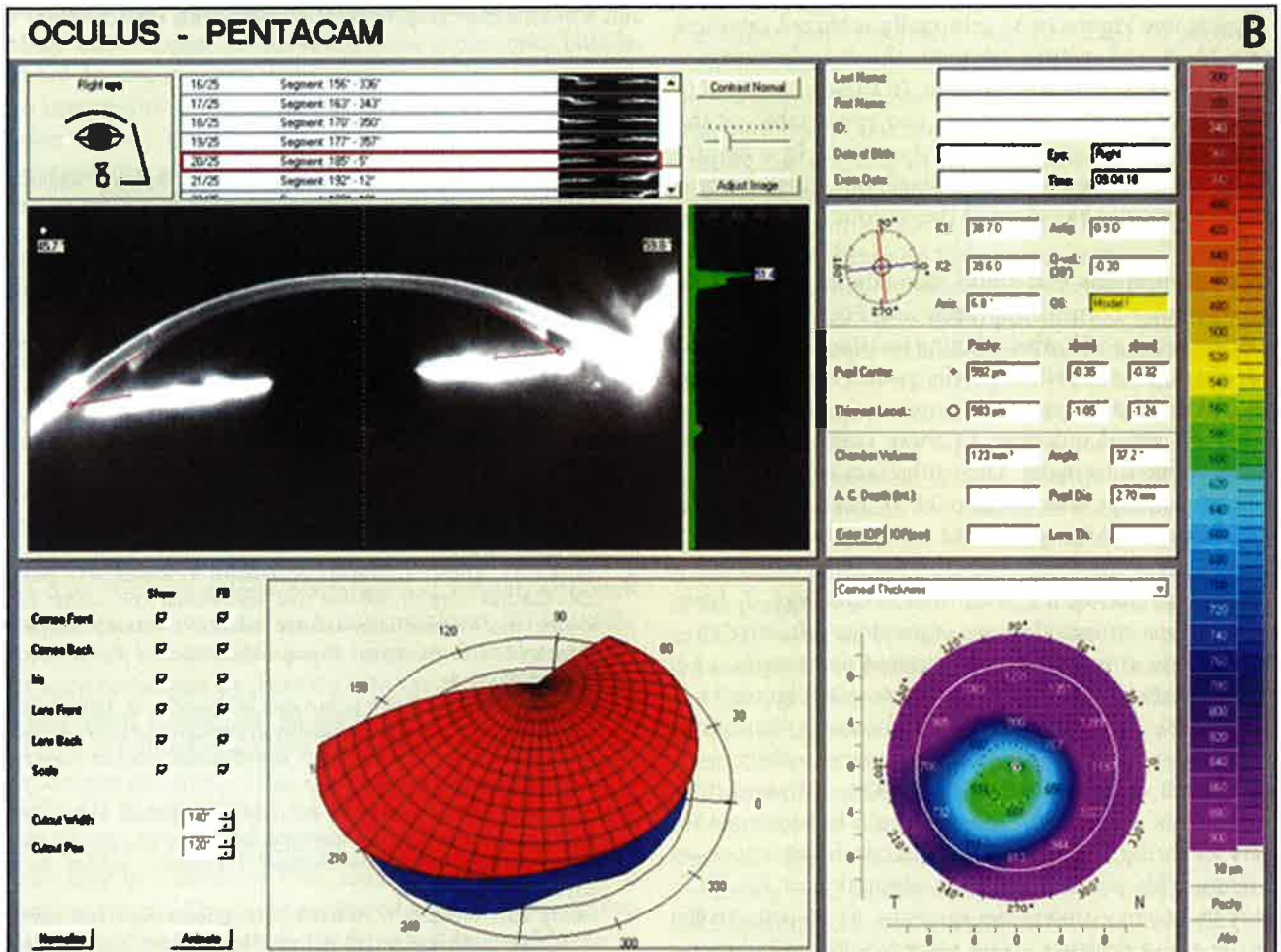
1. Lawless M. The Future of Laser Cataract Surgery. Keynote Lecture. Presented at: American Academy of Ophthalmology Subspecialty Day; November 2012; Chicago, Illinois.
2. Touboul D, Salin F, Mortemousque B, et al. Advantages and disadvantages of the femtosecond laser microkeratome. *J Fr Ophthalmol.* 2005;28(5):535-546. Review.
3. Majid M, Hsu M, Churgin DS. Femtosecond laser-assisted cataract surgery: a current review. *Middle East Afr J Ophthalmol.* 2011;18(4):285-291.
4. Naranjo-Tackman R. How a femtosecond laser increases safety and precision in cataract surgery. *Curr Opin Ophthalmol.* 2011;22(1):53-57.
5. Donaldson KE, Braga-Mele R, Cabot F, et al. Femtosecond laser-assisted cataract surgery. *J Cataract Refract Surg.* 2013;39:1752-1763.
6. Takács AI, Kovács I, Miháltz K, Filkorn T, Knorz MC, Nagy ZZ. Central corneal volume and endothelial cell count following femtosecond laser-assisted refractive cataract surgery compared to conventional phacoemulsification. *J Refract Surg.* 2012;28(6):387-391.
7. Krarup T, Morten Holm L, la Cour M, Kjaerbo H. Endothelial cell loss and refractive predictability in femtosecond laser-assisted cataract surgery compared with conventional cataract surgery. *Acta Ophthalmol.* 2014;92(7):617-622.
8. Abell RG, Kerr NM, Howie AR, Mustaffa Kamal MA, Allen PL, Vote BJ. Effect of femtosecond laser-assisted cataract surgery on the corneal endothelium. *J Cataract Refract Surg.* 2014;40(11):1777-1783.
9. Reddy KP, Kandulla J, Auffarth GU. Effectiveness and safety of femtosecond laser-assisted lens fragmentation and anterior capsulotomy versus the manual technique in cataract surgery. *J Cataract Refract Surg.* 2013 Sep;39(9):1297-1306.



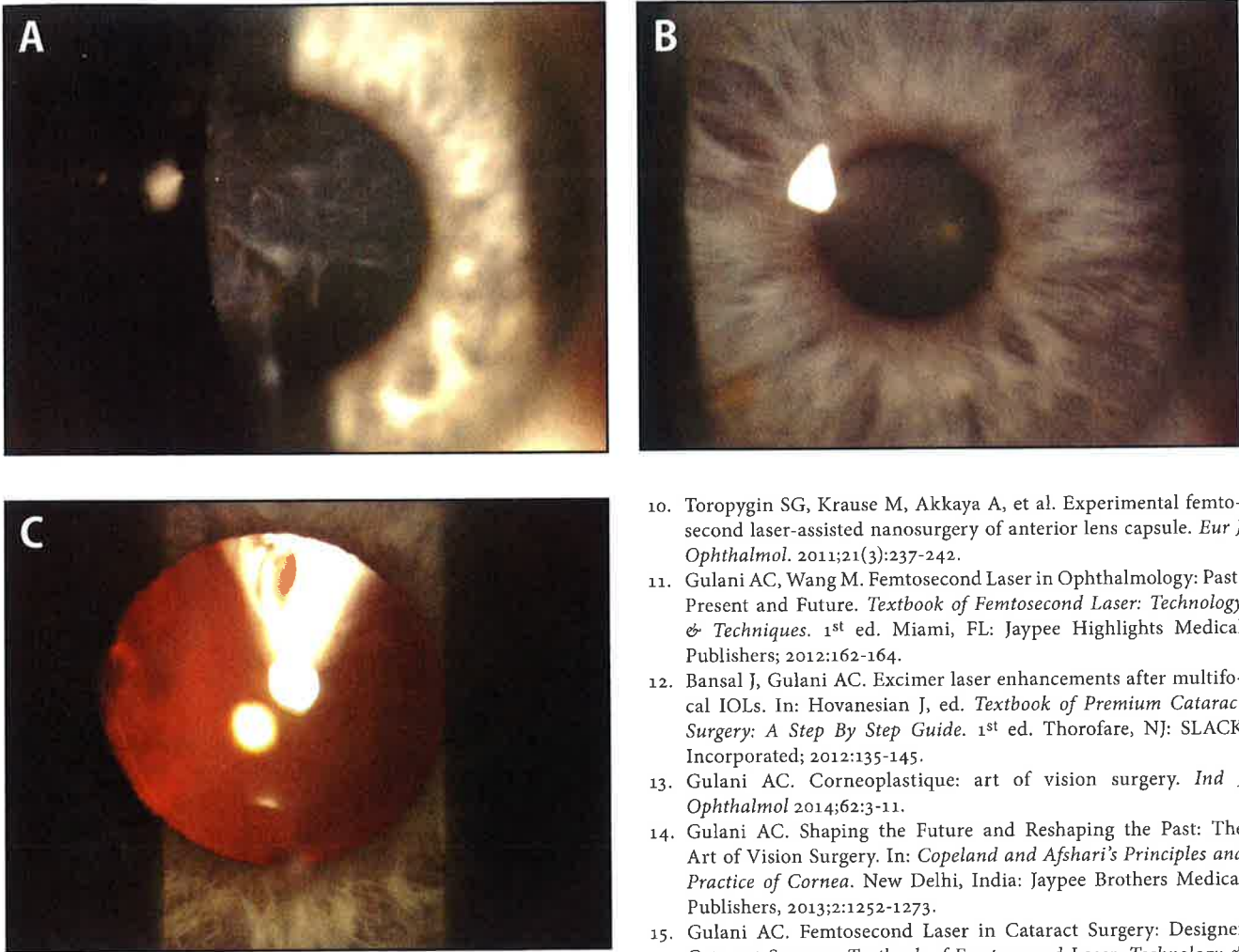
**Figure 14-6.** Femtosecond laser RLE in case of LASIK ectasia with intrastromal corneal ring segments (Intacs).



**Figure 14-7.** (A) Femtosecond laser toric RLE with Descemet's stripping automated endothelial keratoplasty (DSAEK). (continued)



**Figure 14-7 (continued).** (B) Femtosecond laser toric RLE with DSAEK (Pentacam tomography depiction).



**Figure 14-8.** (A) Preoperative: corneal scar with radial keratotomy and high hyperopic astigmatism. (B) Stage I: corneal scar peel (corneoplastique). (C) Stage II: femtosecond laser toric RLE.

10. Toropygin SG, Krause M, Akkaya A, et al. Experimental femtosecond laser-assisted nanosurgery of anterior lens capsule. *Eur J Ophthalmol.* 2011;21(3):237-242.
11. Gulani AC, Wang M. Femtosecond Laser in Ophthalmology: Past, Present and Future. *Textbook of Femtosecond Laser: Technology & Techniques.* 1<sup>st</sup> ed. Miami, FL: Jaypee Highlights Medical Publishers; 2012:162-164.
12. Bansal J, Gulani AC. Excimer laser enhancements after multifocal IOLs. In: Hovanesian J, ed. *Textbook of Premium Cataract Surgery: A Step By Step Guide.* 1<sup>st</sup> ed. Thorofare, NJ: SLACK Incorporated; 2012:135-145.
13. Gulani AC. Corneoplastique: art of vision surgery. *Ind J Ophthalmol* 2014;62:3-11.
14. Gulani AC. Shaping the Future and Reshaping the Past: The Art of Vision Surgery. In: *Copeland and Afshari's Principles and Practice of Cornea.* New Delhi, India: Jaypee Brothers Medical Publishers, 2013;2:1252-1273.
15. Gulani AC. Femtosecond Laser in Cataract Surgery: Designer Cataract Surgery. *Textbook of Femtosecond Laser: Technology & Techniques.* 1<sup>st</sup> ed. J.P. Publishers 2012;20:152-4.
16. Donnenfeld E, Gulani AC. *Femtosecond Laser for Astigmatism Correction during Cataract Surgery.* *Textbook of Femtosecond Laser: Technology & Techniques.* 1<sup>st</sup> ed. Jaypee Brothers Medical Publishers;2012:155-161.