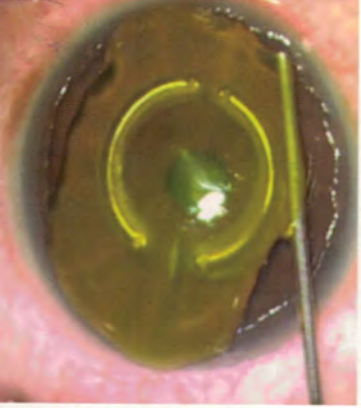

With Interactive DVD-ROM

Mastering Corneal Collagen Cross Linking Techniques (C3-R/CCL/CxL)

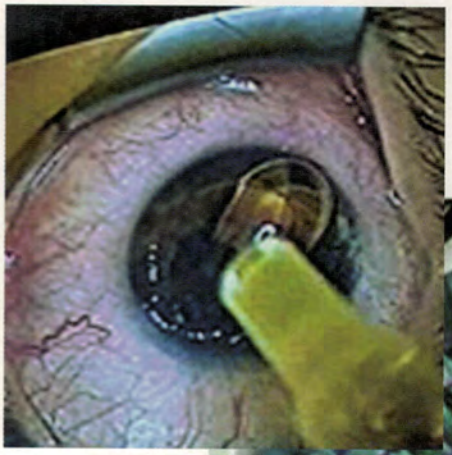

Chapter

19 Re-shaping Keratoconus: Laser PRK followed by Corneal Cross-linking

Arun C Gulani

INTRODUCTION

Keratoconus is a bilateral, noninflammatory corneal disorder that leads to inferior paracentral corneal thinning, inferior corneal steepening, and irregular astigmatism.[1] Although the etiology remains uncertain 14% of cases are associated with a genetic predisposition.

Keratoconic patients could present with complaints of decreased vision, glare, photophbia, and monocular diplopia. External clinical signs of keratoconus include Munson's sign (protrusion of inferior lid on down gaze) and Rizutti's sign (conical reflection on the nasal cornea when light is shone temporally). Slit lamp presentations of keratoconus include inferior paracentral corneal thinning, presence of an ectatic cone within the area of corneal thinning, inferior corneal steepening,Vogt striae (vertical stress lines in the posterior stroma), and a Fleischer ring (iron deposits in the basal layer of the corneal basal epithelium), linear scars can also be seen as result of breaks in Bowman's layer. Breaks in Descemet's membrane can lead to stromal edema and corneal hydrops with intrastromal clefts and vascularization. Resolution of corneal hydrops can lead to corneal scarring. Patients with Keratoconus also have scissoring on retinoscopy and the presence of Charleaux oil droplet reflex, a bright reflex from conical apex surrounded by a dark circular shadow produced by the corneal ectasia.

There are various methods for grading of keratoconus worldwide. The KISA%, created by Rabinowitz provides an algorithm to quantify results from computerized videokeratoscopy to classify whether a patient has keratoconus.[2] McMahon and colleagues and the Collaborative Longitudinal Evaluation of Keratoconus (CLEK) have proposed a method called keratoconus severity score (KSS) for grading of the severity of kerraoconus.[3] New Pentacam Technology (Oculus Inc.) provides parameters that can be further correlated and associated with related anatomy for a more descript diagnostic acumen along with a keratoconus detection software based on relative indices.[4-5]

In this chapter, I shall introduce my classification system that is used in my practice to apply Excimer Laser in a surface ablative (ASA/ PRK) mode for keratoconus and related ectatic disorders.[6-7]

GULANI CLASSIFICATION SYSTEM FOR LASER SURGERY IN KERATOCONUS

Laser as Primary Treatment

(In this subset, the patient is informed that we can strive for vision directly with the laser keeping the surgical interventions noted in Level II as back up plan to be applied in single or combined approaches to address any complication induced or progression of cone if needed)

Class I
Clear Cornea
Class II
Scarred Cornea

Laser as Staged Secondary Treatment

Class I

Following corneal surgery:

a. INTACS
b. Lamellar Keratoplasty
c. Penetrating Keratoplasty
d. C3-R cross-linking
e. Conductive Keratoplasty

Class II

Following intraocular surgery:

a. *Phakic Implant*
   1. Anterior
   2. Posterior
b. *Cataract surgery with lens Implant*
   1. Monofocal
   2. Toric
   3. Presbyopia-corrective

Each case of keratoconus is unique. From their appearance to their topographies and even their refractions, optical effects and aberrations. Over years of numerous clinical and surgical encounters, I found one thing consistent in all of them- "Irregular Astigmatism."

Since I am a firm believer in logic and clinical sense over market-hyped terminologies, I decided to personally approach every case of keratoconus as an asymmetric, high irregular astigmatism associated with other refractive errors ie. Myopia, hyperopia and or presbyopia.[8-9]

Lets first understand why we can or even should use Excimer Laser in a case of proven Keratoconus:
Patients with Keratoconus are frustrated with their vision and resultant life style (especially when they have exhausted their options with glasses and contact lenses). Once they have passed the stage of such non-surgical options, they are facing surgery to rehabilitate their vision.

Among surgical options presented in the current times:

1. Corneal transplant (invasive surgery with long term adverse impact including life style restriction and also little ability to bring patients to uncorrected 20/20 vision).
2. INTACS: Excellent, reversible, less invasive surgery (may even delay or avoid transplant in many cases), but unpredictable in most cases and majority of cases shall need contact lenses and or glasses after the surgery to help patients see.

Given that these patients in most cases are otherwise healthy young adults at the prime of their professional and personal stage in life, we must look at them as people rather than as an eyeball with a book diagnosis.

We must therefore want to provide them the best vision they are capable of and that too without dependence on glasses and contact lenses if possible. Remembering again that they are at their most productive stages of their life and just like our refractive patients must be encouraged to lead a visually independent life.

Here, we need to balance our desire to provide an enhanced lifestyle with our honest intention to keep safety for these patients utmost in our minds.

If selecting a choice of INTACS for these patients since compared to a corneal transplant it is less invasive and more promising visually, we are doing the right thing and explaining to patients that they will come close to 20/40 and also that they shall need contact lenses and or glasses. This is a fair choice for someone who despite a hard contact lens trial does not see better than 20/40 preoperatively.

But what about the keratoconic patient who has passed the non-surgical option (CLs and glasses) stage and yet sees 20/20 best corrected?

In such cases, how are we justified in doing an approved procedure like INTACS (since we have to do something now that this patient cannot function with contact lenses or glasses) to make their vision worse ie.20/40 from their preoperative potential of 20/20?

This is where I find a place for the Excimer Laser.
Using the Excimer Laser in a surface mode (no LASIK in any case or any flap cutting) we can address the Keratoconus as what I call "Astigmatism gone wild" to "Tame" it to a shape resulting in excellent unaided vision.

Yes, theoretically the Excimer Laser will remove tissue and so accelerate the Keratoconus but we also delivering 20/20 unaided vision (remember this 20/20 may not ever match the 20/20 of our simple Lasik cases but coming to unaided 20/20 from legal blindness for a Keratoconus patient is visibly, sheer ecstacy) to these very affected patients for the first time in their life.

Here is the discussion with the patient: This is an option because you do meet the criteria for Laser surgery. If after laser surgery (no one can guarantee the duration that this will last) your vision does drop from 20/20 to 20/40 or worse either by natural progression or by the Laser surgery that you had then you fit the criteria for INTACS surgery.

Again, keeping in synch with my corneoplastique concepts, all of the mentioned surgeries available out there can always be used a back up. The patient never loses candidacy for them.

This discussion underscores the honest desire to help keratoconic patients lead a productive life of visual freedom knowing that there are back up plans in place.

Also with the application of Collagen Cross-linking (C3-R) , we may be able to arrest these keratoconic corneas after Laser Surgery in the final shape created to prevent progression in the future.

So keeping the above discussion in mind lets see how to apply these concepts in everyday practice.

I have used technologies including Pentacam anterior segment analyzer, multiple types of corneal topographers, wavefront technologies, Optec6500 and Visual simulators that zero in on cases that are obvious. Nevertheless, the Keratometer, Refractive retinoscopy and hard contact lens trial are a very important adjunct forming the mainstay of detection, grading and treatment selection.[10-11]

Simply put, if we start approaching every keratoconus as a form irregular astigmatism, we can apply the methodology of thought process and surgical

planning towards excellent visual outcomes. The corneal surface can be recontoured with an excimer laser in cases of keratoconus. This approach of correcting corneal architecture and finally shaping the contour with an Excimer Laser falls under the realm of my concept of Corneoplastique™.[12-15]

Numerous studies in scientific literature have investigated the use of laser treatment for keratoconus to give patients better and more comfortable vision with and without glasses or soft contact lenses. In these studies, the authors hope to avoid or delay the need for corneal transplant in keratoconus eyes, giving these patients better vision with and without glasses or soft contact lenses.[16] Further more, it was found that Excimer laser surgery can improve vision and the ability to wear contact lenses, and does not interfere with subsequent corneal transplantation surgery.[17] The downside to PRK is that it is not a standard treatment for keratoconus.

Rather, it is controversial because the procedure thins out the cornea. In keratoconus, the cornea is already thin and unstable and additional tissue removal can cause further progressive distortion. However, the Excimer laser may have potential therapeutic benefit in removing certain corneal scars. Some studies suggest that PRK may have a role in very mild and stable sub clinical keratoconus. Regardless, Excimer treatment in these instances is done selectively on a case-by-case basis.

I have successfully treated all types of keratoconus (the grade of severity does not matter as much as the parameters listed below) with surface laser vision surgery (ASA/PRK) by simply approaching them as a case of assymteric irregular astigmatism.

We have devised a set of criteria for Excimer Laser PRK surgery for Keratoconus.

Gulani- Nordan criteria for Laser PRK in Keratoconus:

- Patient is symptomatic with poor visual acuity and double vision or glare and cannot tolerate contact lenses (meaning the options of gasses or contact lenses has run out for any number of reasons).
- Clinical examination and signs suggesting corneal shape irregularity.
- Best corrected visual acuity of 20/30-20 (even if with hard contact lens trial). Best corrected vision below 20/40 would indicate INTACS.
- Refraction is stable (with review of prior documented exams).
- Astigmatism Higher than Myopia/ Hyperopia preferred.
- Corneal thickness is more than 400 µm in the thinnest part and also after laser shall be preferably not less than 350.
- Corneal scar even if present is less than the anterior one third in depth.[18]
- Patient 's understanding that using the Excimer laser is an "off-label" use and that if for some reason (due to laser or natural progression) if their keratoconus worsens then they would be candidates for INTACS/ LK/ PKP in that order of decreasing selection.

If these criteria are met, I design a plan to correct this corneal shape and surface irregularity with the Excimer laser.

Even though I have treated practically every grade and combination of keratoconus with or without associated surgeries in stages or previously done elsewhere, in this chapter I shall limit myself to a discussion for primary laser PRK on Keratoconus and briefly mention the spectrum of Laser applications in combination approaches for the full spectrum of Keratoconus surgical care.

DISCUSSION AND RESULTS

All the cases were confirmed Keratoconus with present day criteria inclusive of topography and we did not differentiate treatment based on stage. Rather, we used my consistent approach based on visual potential and corneoplastique approach along with the classification system.

In this study we included 14eyes of 10 patients (9 males and 5 females) ranging in age from 20-66 years old with follow-up ranging from 6 months to 3 years.

Each of these patients underwent Surface Excimer Lasr (PRK / ASA) using standard protocol. No variance from my PRK technique was used in any of these cases.[19] Following a normal PRK postoperative course, 13 out of 14 eyes achieved uncorrected vision of 20/20, one of the fourteen eyes achieved uncorrected vision of 20/40 (which was her best corrected vision preoperatively due to amblyopia) and 6 eyes of the 13 eyes at 20/20 achieved uncorrected vision of 20/15 (Figs 19.1 and 19.2A and B).

The point I want to stress here is that the postoperative evaluation of success of this treatment is

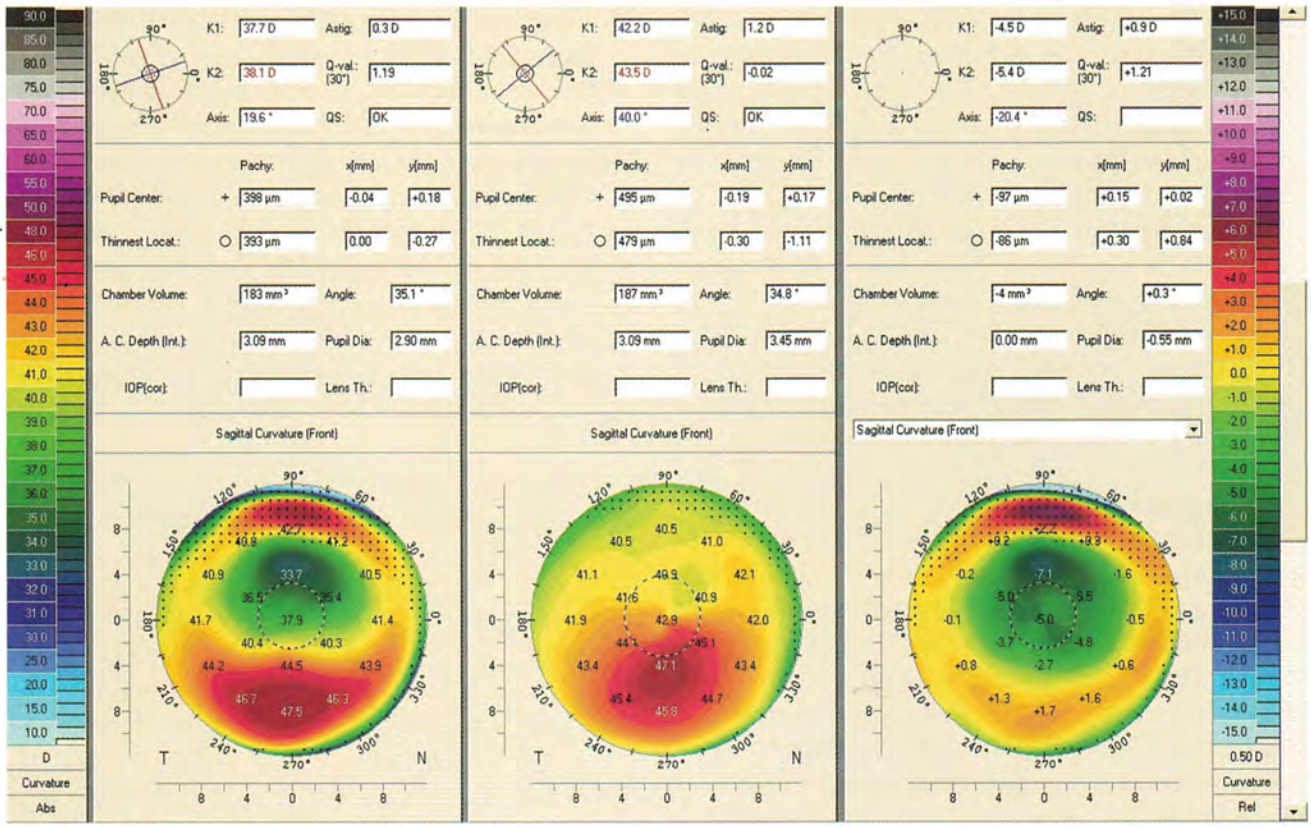

Figure 19.1: Laser PRK for Keratoconus (preop and postop topographies with Differential map). Post op vision Unaided 20/15

based entirely on the uncorrected visual acuity and subjective response of the patient. Patients were asked to grade the vision compared to before laser surgery on the grade of 1 to 10 (10 being the best). All the patients treated with this approach placed a subjective evaluation grade of 10 or more.

All of the patients stated that they had no complaints at night and all of them noted that their vision at night was improved compared to best corrected vision preoperatively.

In all cases, Excimer Laser ablation resulted in postoperative corneas no thinner than 350 microns, which is enough to rehabilitate the cornea or perform any other corneal surgery in the future ie INTACS (Figs 19.3A and B).

One can also treat patients previously operated with INTACS to correct residual astigmatism with laser vision surgery in the PRK mode.

Lets analyze this concept. The fact that the Keratoconus or corneal ectasia has been stabilized by the INTACS (acting as braces) allows us to shape the cornea just a little more (of course contact lenses and glasses are the non-interventional options here) since astigmatism removes the least amount of tissue when ablated with the Excimer Laser. Also since the inner optic zone for Intacs is 7mm - 7.2mm, the laser ablation zone can be extended to 6.5mm without eroding the superior roof of the INTACS (Figs 19.4A and B).

INTACS is an excellent way to correct or minimize the ectasia but since it is an *inaccurate surgery* (even though most patients do well, we cannot predict who will do well, how well and by when); I reserve it for patients with Keratoconus who are best corrected to 20/40 or less (Gulani AC. INTACS : A Refractive Surgery to Prepare and Repair. INTACS Round Table. ASCRS, May 2007)

Surgical techniques other than Penetrating Keratoplasty have been suggested for management of keratoconus with variable success besides Laser surface ablation,[20-23] intrastromal rings,[24-26] intraocular lens,[27] keratotomies,[28] and lamellar keratoplasty.[29-30] Collagen cross-linking of the cornea has also been

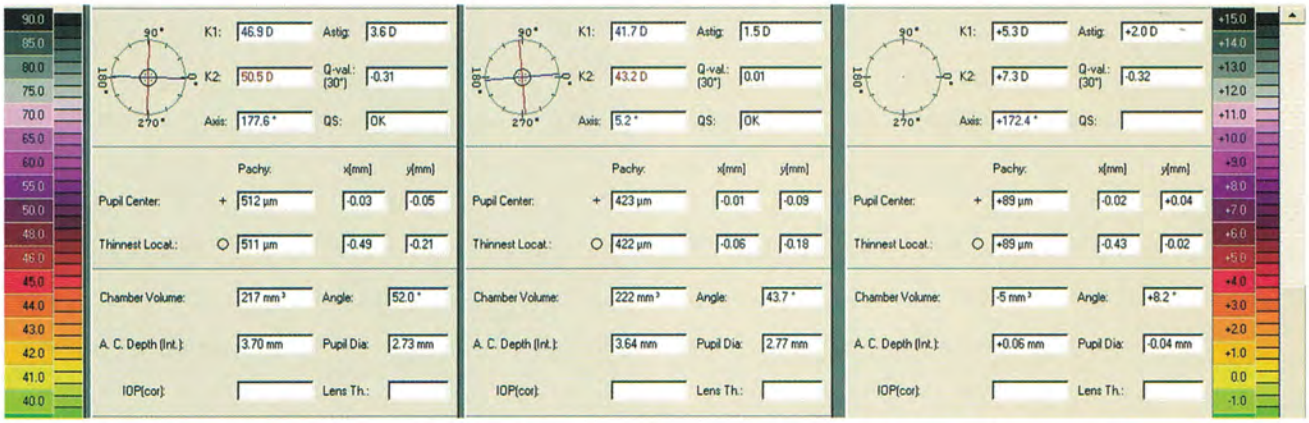

Figure 19.2A: Laser PRK for Pellucid Marginal Degeneration Patient (preop and postop topographies with differential map). Post op vision Unaided 20/15

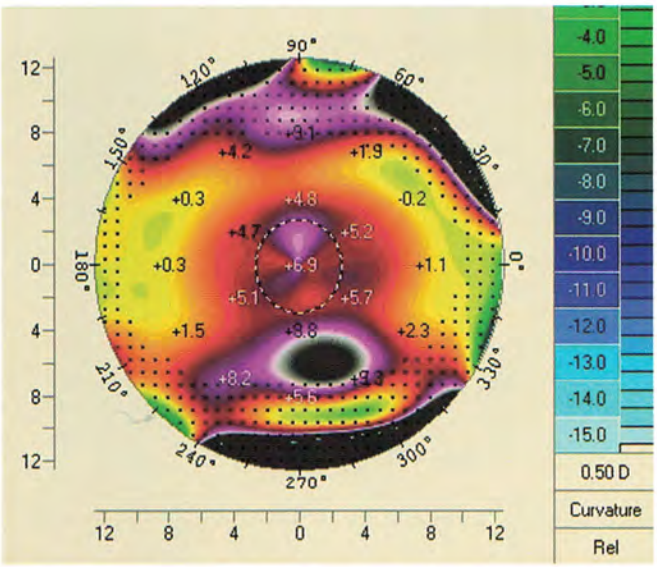

Figure 19.2B: Differential map of same patient

introduced to halt the progression of ectasia in keratoconus.[31-32]

C3-R® (COLLAGEN CROSS-LINKING)

Wollensak et al[33] is credited with the seminal study that showed that corneal cross-linking (exposure to UV-A light at 3.0 mW/cm^2 and riboflavin 0.1% for 30 minutes) was able to stop progressive keratoconus in all 23 eyes of 22 eyes. The patients ranged in age from 13 to 58 with the average age 34.7 ± 11.9 years. Steep keratometry values reduced from 2.01 diopters was also seen in 70% of eyes with a refractive correction of 1.14 diopters. Over an average follow-up time of 23 months, no scarring in cornea, no lens opacities (i.e. no cataracts), and no endothelial cell loss were seen. Intraocular pressure did not change post-operatively.

Five year follow-up results to the 3 year study have been published in Wollensak's review of cross-linking.[34] In 150 eyes treated so far, 60 have 5 year follow-up and no progression of keratoconus has been seen in any of these patients. In 31 eyes (52%), a reduction in keratometry of 2.87 diopters was seen with best-spectacle corrected visual acuity (BSCVA) improving by 1.4 lines in these eyes. Other clinical studies in the United States, Italy, Brazil, and England have been smaller with shorter follow up, but are consistent with the above cited studies in terms of efficacy and high safety profile.

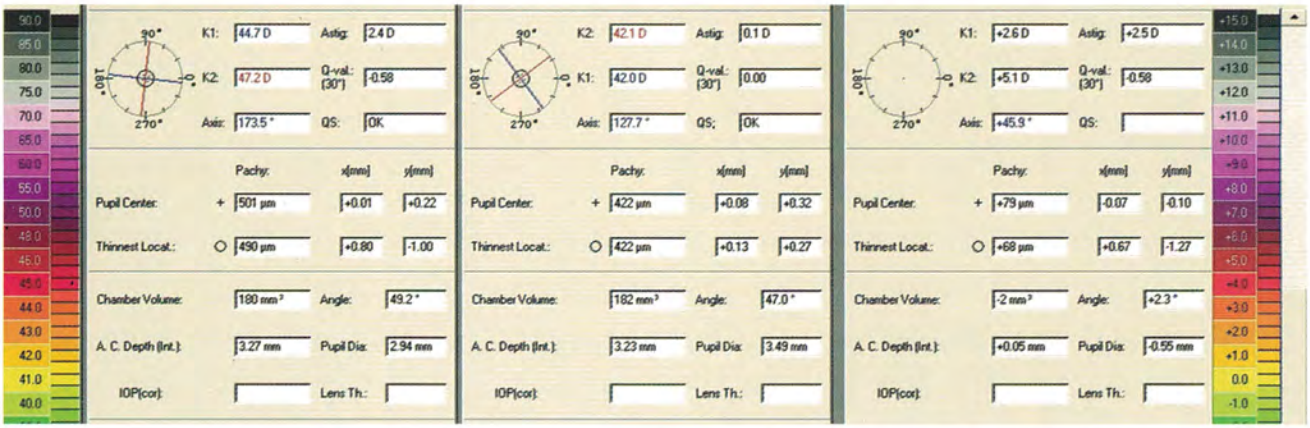

Figure 19.3A: Laser PRK for Keratoconus (preop and postop topographies). Post op vision Unaided 20/15

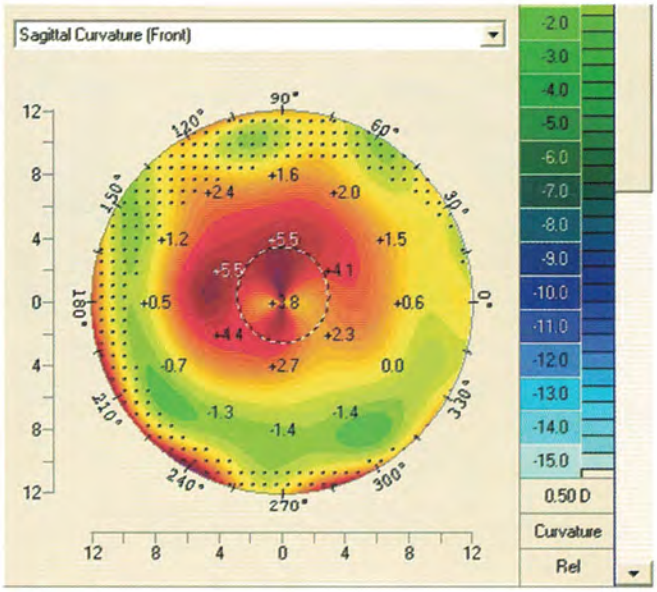

Figure 19.3B: Differential map of same patient

We observed that the corneal topography changes post-treatment indicated preferential flattening over the cone. Targeted flattening consistently occurs over the steepest part of the cone with less flattening on less steep areas. Corneal coupling occurs in many patients after C3-R®, which is similar to, but less consistent than single segment Intacs® placement. With C3-R®, if the cone is located inferiorly, than flattening can occur inferiorly and superior steepening may occur as well. This coupling effect (flattening below and steepening above) results in better corneal symmetry and BSCVA afterwards. There have been individual case reports of dramatic improvement in BSCVA without impressive changes in topography. These observations may be explained by the optical regularization of the cornea resulting from cross-linking.

It is worth noting that 99% primary keratoconus and keratoectasia (LASIK-induced ectasia) patients treated to date have been stabilized after a one-time C3-R® procedure. There have been some patients with very aggressive forms of ectasia that required a second C3-R® treatment to achieve stabilization. It almost seems too good to be true, but the results from multiple ophthalmologists around the world are remarkably consistent.

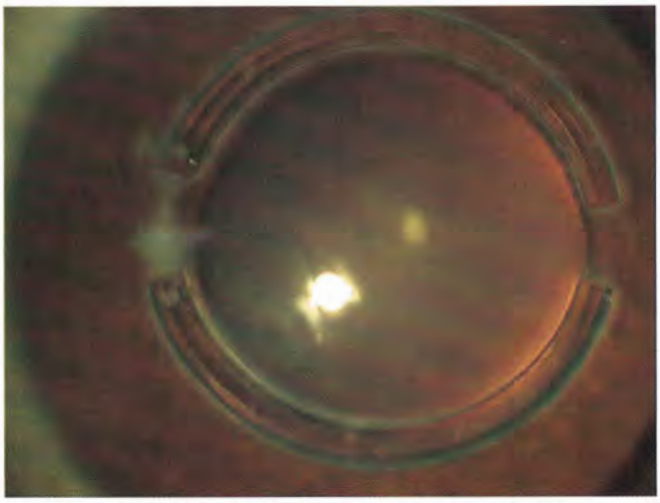

Figure 19.4A: Laser post INTACS Clinical picture

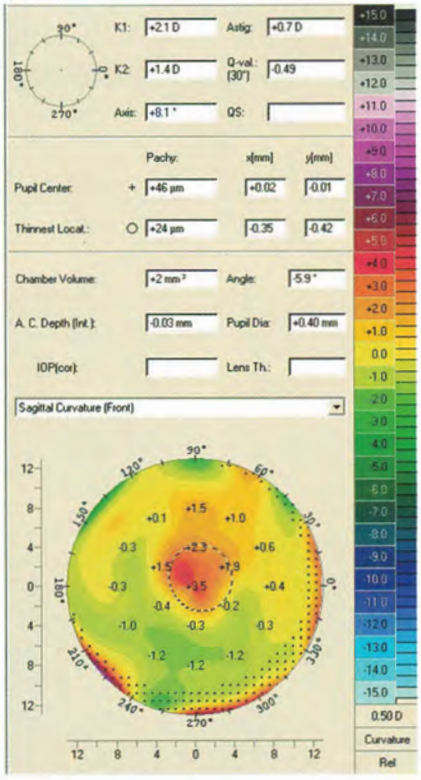

Figure 19.4B: Differential topography map of Laser post INTACS, same patient with vision unaided 20/25

BOXER WACHLER 10 STEP C3-R® PROTOCOL

Treatments may be performed unilaterally or bilaterally at the same time if C3-R® is indicated for both eyes. If one eye is to be treated, the fellow eye is taped closed and covered. We performed the procedure per our protocol described below. Although somewhat labor-intensive to perform (application of riboflavin solution every 3 minutes for a total of 30 minutes), this is the necessary means to achieve the desired effect for patients.

1. The UVA device is periodically calibrated with a UVA meter to ensure that the irradiation is 3.0 mW/cm2 ± 0.3.
2. Topical anesthesia is administered. Tetracaine 0.5% works well as it loosens the epithelial cell tight junctions to facilitate penetration of riboflavin into the stroma with intact epithelium.
3. Two surgical spear-type sponges are made "soppy wet": one sponge with 0.1% riboflavin solution and the sponge with Tetracaine.
4. Tetracaine is applied to the eye which is then closed for 5 minutes to allow preliminary superficial riboflavin absorption ("pre-soaking"). Note: when a procedure is not being performed, the bottle of riboflavin solution is stored in a refrigerator as it is prudent to avoid unnecessary external light exposure.
4. A speculum is inserted to expose the eye and the patient is instructed to look at the center of the lights.
5. The UVA light is positioned on the cornea at the proper distance from the eyes. The working distance varies according to the device used. The irradiation is performed for 30 minutes.
6. The "soppy wet" sponge soaked with riboflavin is wiped on the cornea every three minutes. The "soppy wet" sponge soaked with Tetracaine is applied every 10 minutes for patient comfort.
7. After 30 minutes, the device is turned off and the speculum is removed.
8. Artificial tears are applied and the patient asked to keep eyes closed for 5 minutes to allow lubrication of the corneal surface.
9. The patient is advised to spend to rest of the day keeping his or her eyes closed.
10. Patients are given valium (or other benzodiazepine) to promote sleeping when arrival at home or the hotel room for out of town patients. A dilute bottle of anesthetic drops is given to the patient that can be used every 20 minutes as needed. Often these drops are not used by patients because recovery is typically comfortable. This bottle should be discarded after two days because there are no significant amounts of preservatives.

Patients can expect some mild foreign body sensation for the remainder of the day. Pain does not occur with the epithelium-on technique, which is our technique (see below for more details on this technique compared to epithelium-off). On the next day exam after C3-R® with epithelium-on, slit lamp biomicroscopy of the cornea appears completely normal or rarely may reveal a few areas of scattered punctate epitheliopathy. Mild foreign body sensation or grittiness may be present on the first day that will resolve in a day or two. Patients may be examined again at 3 months and again at 1 year. On occasion, patients may be examined at a more frequent basis.

If C3-R® is being performed with epithelial removal, initially a 7 mm corneal abrasion is created first after topical anesthetic is given. The procedure is then performed as described above. At the end of the procedure, a bandage contact lens is placed for 3-7 days while the epithelium heals. Analgesic medication is necessary as patients often experience pain during these days of epithelial healing.

The wide spectrums of applications are only limited by our logic and imagination. I also want to point out that by logic, I do mean responsible thinking and knowledge of anatomy, optics and physiology in selecting the most appropriate surgery or surgeries and keeping in mind that they be synergistic towards a visual goal.[35]

Approaching the cornea of a patient as an asymmetric high irregular astigmatism and by applying simple inclusion criteria we are not only clear in our head about the treatment as a refractive surgeon but we are helping patients to understand that keratoconus is an approachable condition despite its progressive nature with surgical options at every stage to help the patient live a continued, productive life.

Applying our classification system we can therefore address practically all presentations of Keratoconus. For example in cases outlined above the Excimer Laser can be used as a primary surgery for Keratoconus on clear corneas (Class I) or scarred corneas (Class II). In some cases we may need to build the cornea in strength, scar removal and tissue replacement ie. Lamellar Keratoplasty (Fig. 19.5) or Penetrating Keratoplasty (Fig. 19.6) and then present for Excimer laser surgery (Classification system Class I) or in specific

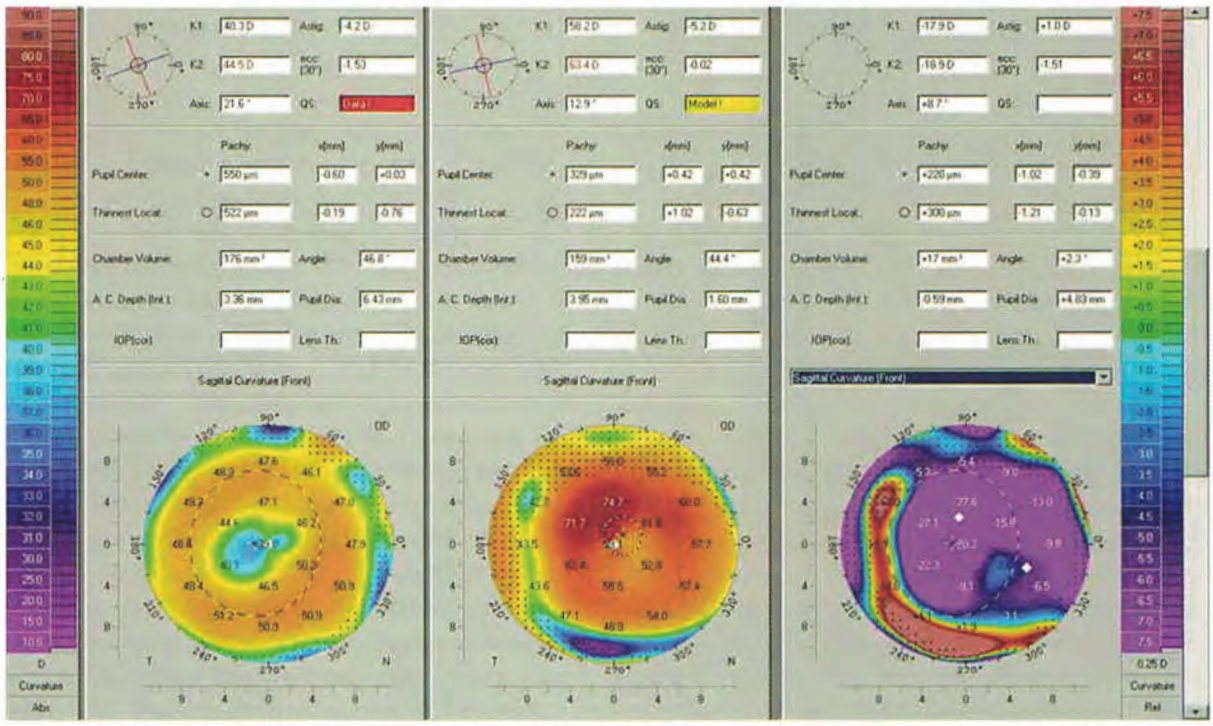

Figure 19.5: Lamellar keratoplasty to strengthen a case of very thin keratoconic cornea (222 microns) and also to decrease keratometry by nearly 20 D). This case is now ready for Laser PRK for residual refractive error to achieve excellent unaided vision

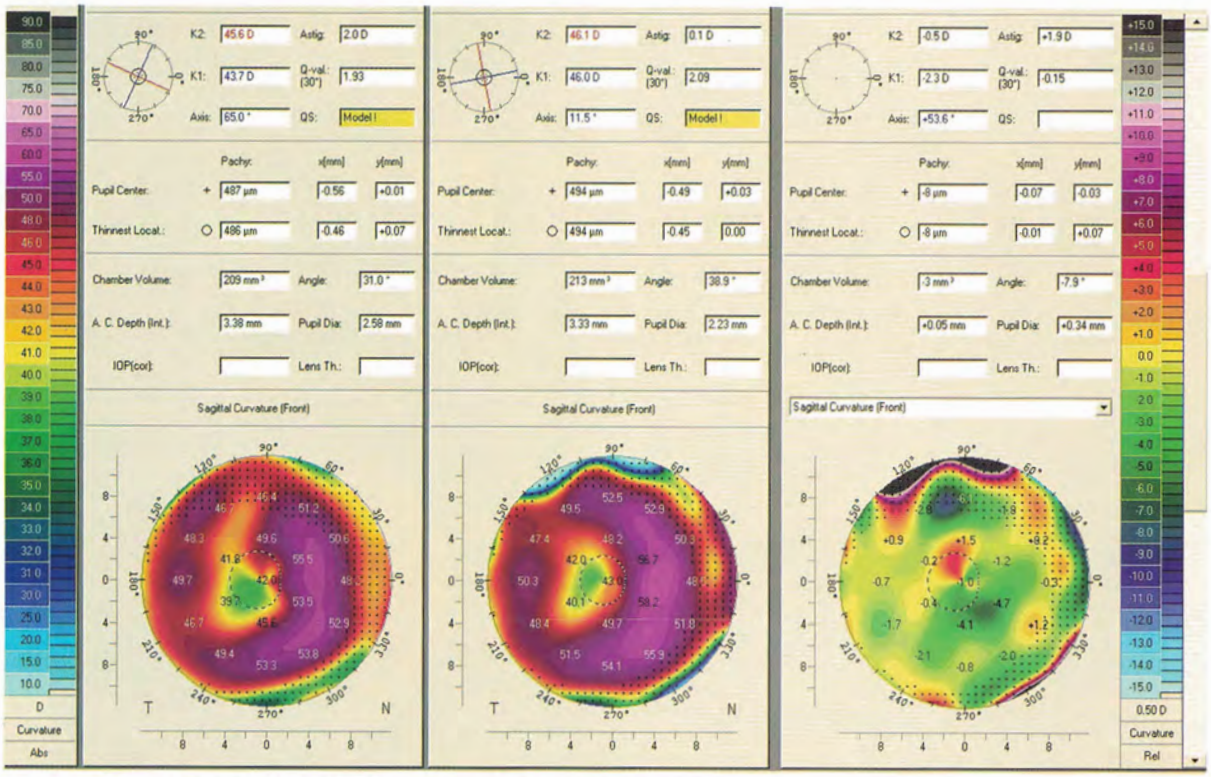

Figure 19.6: Penetrating Keratoplasty for a case of Keratoconus with very thin and full thickness scarred cornea as Stage I, followed by Laser PRK to unaided 20/20 vision. Topography picture post Laser PRK

cases we can prepare in a cataractous age population to customize their cataract surgery in manipulating the optics intra ocularly (i.e. Toric IOL) and then addressing the final refractive residual error on the cornea (Class IIb) (Fig. 19.7).

C3-R®, A MANDATED STAGE II FOLLOWING THE RESHAPING OF KERATOCONUS?

I can envision a future wherein a keratoconic cornea once brought to its desired shape by the Excimer Laser in a PRK / ASA mode, INTACS or Conductive keratoplasty or even after corneal building procedures like Lamellar Keratoplasty followed by Excimer PRK/ ASA can then undergo C3-R treatment for cross-linking into a more stable and long lasting effect.

The use and indications for C3-R® will only expand as we use it not only for primary treatments but also for solidifying modified shapes as a secondary mandated procedure. For example, applying C3R®,

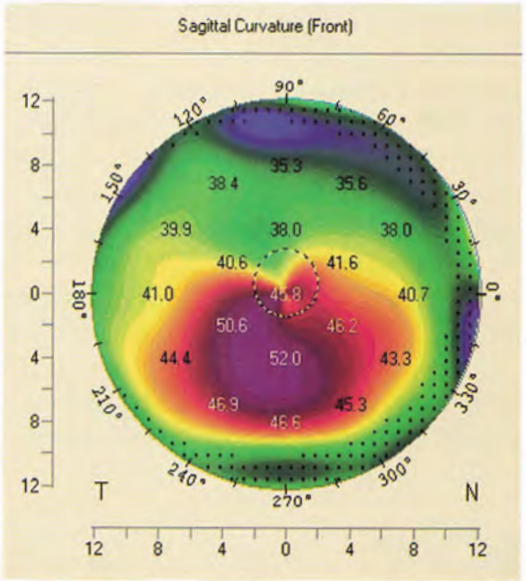

Figure 19.7: Toric IOL was performed in this elderly male as Stage I to correct high myopia, cataract and high astigmatism.in this case followed by Laser PRK for residual astigmatism to unaided 20/20 vision. Differential Map picture

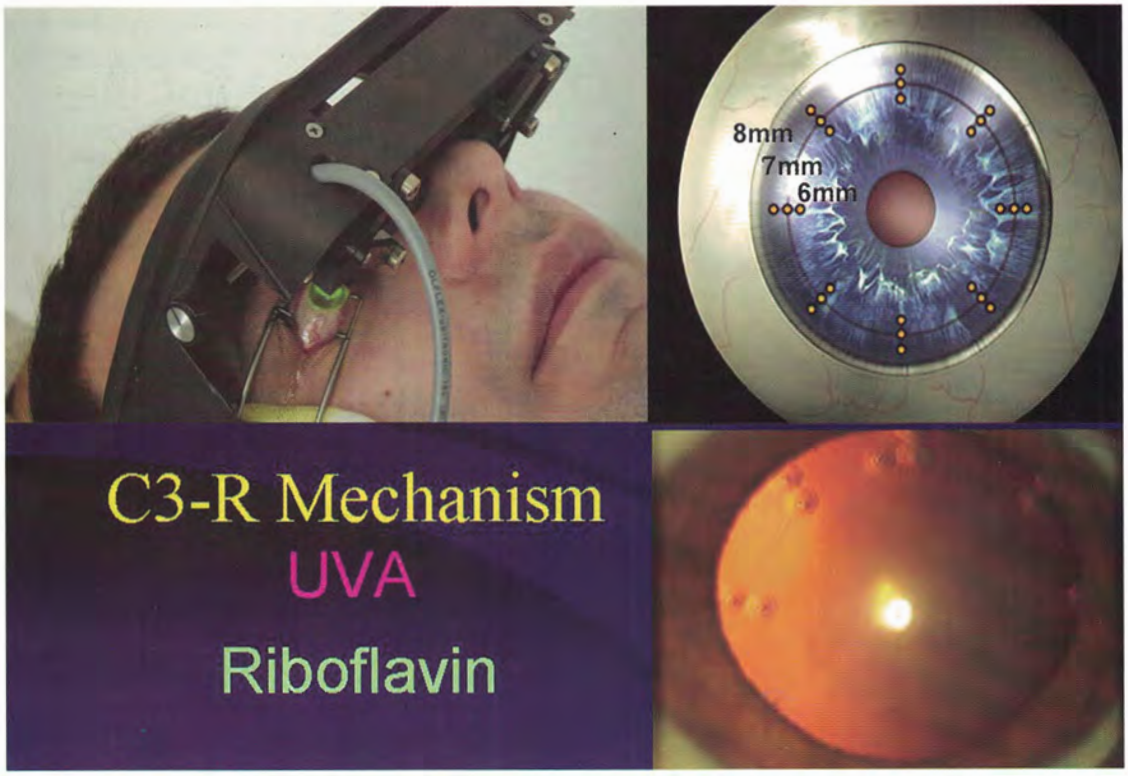

Figure 19.8: Conductive Keratoplasty was performed in this patient followed by C3R cross-linking

can also be done on a keratoconic cornea treated previously with conductive keratoplasty (Class II e) (Fig. 19.8).

Studies are needed for long term impact to make Stage II C3-R® a future mainstream application.

These very principles follow the concepts that have been brought together under my concepts of Corneoplastique™ wherein topical, brief, elegant, aesthetically pleasing, least invasive surgeries are used singly or in stages towards a goal of unaided emmetropia. Corneoplastique prepares for the final fine tuning using the Excimer Laser towards a visual goal where early rehabilitation and aesthetic outcomes are essential, with promising uncorrected visual acuity.[36-41]

REFERENCES

1. Krachmer JH, Feder RS, Belin MW. Keratoconus and related noninflammetory corneal thinning disorders.Surv Ophthalmol 1984;28(4):293-322.
2. Rabinowitz YS, Rasheed K. KISA% index:a quantitative videokeratography algorithm embodying minimal topographic criteria for diagnosing keratoconus.J Cataract Refract Surgg 1999;25(10);1327-35.
3. McMohan TT, et al. A new method for grading the severity of keratoconus: the Keratoconus Severity Score (KSS). Cornea 2006;25(7):794-800.
4. Gulani AC, Holladay J, Belin M, Ahmed I. Future Technologies in LASIK- Pentacam Advanced Diagnostic for Laser Vision Surgery. In Experts Review of Ophthalmology 2008- London (in Press).
5. Gulani AC. " Pentacam Technology in Lasik"- Corneal Refractive Surgery in Video Atlas of Ophthalmic Surgery. XVII. 2008;(2).
6. Gulani A C. Pentacam Technology in Full Spectrum of Refractive Surgery: KMSG International Conference, Madrid, Spain. June 2006.
7. Gulani A C. Pentacam - Basics and Advanced Course: Proceedings of Florida State of Ophthalmology Conference. Naples, Florida. Aug 2006.
8. Gulani AC. Corneoplastique™ Advanced Corneal Surgery Course. SASCRS- Durban, South Africa; Aug 2005.
9. Gulani AC. Corneoplastique™: art of Vision Surgery (abstract) ISOPT, Berlin, Germany March 2006.
10. Nordan LT. Keratoconus: Diagnosis and Treatment. Arch Ophthalmol 1996;114(2):135-41.
11. Nordan LT. Keratoconus and Lasik: Ambiguiuty has no place in Keratorefractive surgery: Cataract and Refractive Surgery today 2006.
12. Gulani AC. Corneoplastique™. Techniques in Ophthalmology 2007;5(1):11-20.

13. Gulani AC. "A New Concept for Refractive Surgery: Corneoplastique" Ophthalmology Management 2006;57-63.
14. Gulani AC. Corneoplastique: Art of Vision Surgery (Abstract). Journal of American Society of Laser Medicine and Surgery 2007;19:40.
15. Gulani AC. "Corneoplastique" Video Journal of Cataract and Refractive Surgery. Vol XXII. Issue 2006;3.
16. Excimer laser photorefractive keratectomy for treatment of keratoconus . J Mortensen, A Ohrström J Refract Corneal Surg (Vol. 10, Issue 3:368-72.
17. Appiotti A, Gualdi M Treatment of keratoconus with laser in situ keratomileusis, photorefractive keratectomy, and radial keratotomy. J Refract Surg 15:S240-2.
18. Gulani AC. Combined corneal scar excision, PRK surgery seeks unaided emmetropia. Ocular Surgery News. Cornea and External disease section, June 2008.
19. Gulani AC. Excimer Laser PRK: Refractive Surgery to the Rescue. In Textbook- Mastering Advanced Surface Ablation Techniques. J P Publishers 2007;26:246-48.
20. Buzard KA, Tuengler A, Febbraro JL. Treatment of mild to moderate keratoconus with laser in situ keratomileusis. J Cataract Refract Surg 1999;25:1600-1609.
21. Kasparova EA, Kasparov AA. Six-year experience with excimer laser surgery for primary keratoconus in Russia. J Refract Surg 2003;19(suppl):250-54.
22. Mortensen J, Carlsson K, Ohrstrom A. Excimer laser surgery for keratoconus. J Cataract Refract Surg 1998;24:893-98.
23. Cochener B, Le Floch G, Volant A, Colin J. Le laser Excimer peut-il tenir une place dans le traitement du keratocone? [Could the laser excimer have a place in the treatment of keratoconus?]. J Fr Ophtalmol 1997;20:758-66.
24. Colin J, Cochener B, Savary G, Malet F. Correcting keratoconus with intracorneal rings. J Cataract Refract Surg 2000;26:1117–22.
25. Siganos D, Ferrara P, Chatzinikolas K, et al. Ferrara intrastromal corneal rings for correction of keratoconus. J Cataract Refract Surg 2002;28:1947-51.
26. Alio JL, Artola A, Ruiz-Moreno JM, et al. Changes in keratoconic corneas after intracorneal ring segment explantation and reimplantation. Ophthalmology 2004;111:747–51.
27. Sauder G, Jonas JB. Treatment of keratoconus by toric foldable intraocular lenses. Eur J Ophthalmol 2003;13:577-79.
28. Bowman CB, Thompson KP, Stulting RD. Refractive keratotomy in keratoconus suspects. J Refract Surg 1995;11:202-6.
29. Busin M, Zambianchi L, Arffa RC. Microkeratome-assisted lamellar keratoplasty for the surgical treatment of keratoconus. Ophthalmology 2005;112:987-97.
30. Watson SL, Ramsay A, Dart JK, et al. Comparison of deep lamellar keratoplasty and penetrating keratoplasty in patients with keratoconus. Ophthalmology 2004;111:1676-82.
31. Wollensak G, Spoerl E, Seiler T. Riboflavin/ultraviolet-A induced collagen cross-linking for the treatment of keratoconus. Am J Ophthalmol 2003;135:620-7.
32. Mazzotta C,Balestrazzi A,Traversi C,et al. Treatment of progressive keratoconus by riboflavin-UVA-induced cross-linking of corneal collagen: ultrastructural analysis by Heidelberg Retinal Tomograph II in vivo confocal microscopy in humans.Cornea 2007;26940:390-97.
33. Wollensak G, Spoerl E, Seiler T. Riboflavin/ultraviolet-A-induced collagen cross-linking for the treatment of keratoconus. Am J Ophthalmol 2003;135:620-27.
34. Wollensak G. Cross-linking treatment of progressive keratoconus: new hope. Curr Opin Ophthalmol. 2006;17:356-60. Review.
35. Gulani AC. Principles of Surgical Treatment of Irregular Astigmatism in Unstable Corneas. TextBook of Irregular Astigmatism . Diagnosis and Treatment . Thorofare , NJ: SLACK Incorporated 2007;251-61.
36. Mertens E, Gulani AC, Karpecki P. The Orbscan Technology. In Textbook- Mastering Techinques of LASIK, EPILASIK and LASEK. Techniques and Technology. J.P. Publishers 2007;98:310-20.
37. Gulani AC, McDonald M, Majmudar P, Koch D, Packer M, Waltz K. "Meeting the challenge of Post-RK patients"- Review of Ophthalmology 2007; IV(10):49-54.
38. Mertens E, Gulani AC. Post – Lasik corneal ectasia: In Textbook- Mastering the Techniques of Customized Lasik. J P Publishers 2007;31:284-93.
39. Gulani AC, Alio J, et al. "Abnormal Preoperative Topography in Refractive Surgery Complications: Cataract and Refractive Surgery Today Journal 2007;7(2)37-42.
40. Gulani AC. "How to put logic into action after Lasik"- Review of Ophthalmology 2006;XIII(9):60-64.
41. Gulani AC, Wang M. Future of Corneal Topography. Textbook of Corneal Topography in the Wavefront Era. Slack Inc 2006;26:303-304 Slack Inc.