

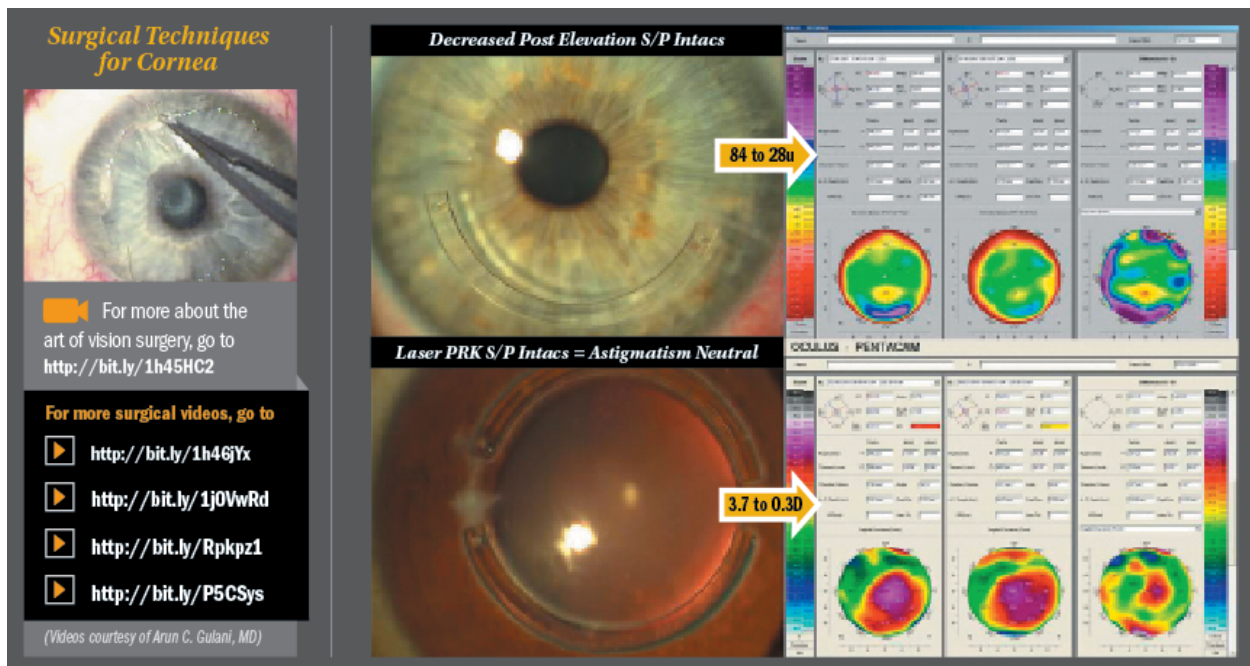
# Ophthalmology Times

CUTTING-EDGE ADVANCEMENTS

## Repairing, preparing the cornea as vision rehabilitative platform

Second in two-part article addresses surgical approach to decoding corneal scars

*Gloves Off With Gulani by Arun C. Gulani, MD*



As in each column, let us first begin with our mindset. I'd like to present the cornea as an elegant, optically powerful, and visually focused organ, easily accessible for shape modification that translates directly to unaided visual acuity.

Let us presume also a mindset that thinking about performing a penetrating keratoplasty (PKP) is akin to giving up, losing the battle, or not even venturing to design vision in the patient's best interests. Unless there is a through-and-through corneal pathology/perforation from whatever cause (trauma, infection, surgical complications, degeneration, etc.), a penetrating corneal transplant should be the last resort of corneal rehabilitative techniques.

As I have said before, PKP can be compared with opening the entire abdomen as opposed to elegantly approaching individual structures with the least interventional attitude. It does not

The composite image illustrates the use of Intacs for ALK ectasia. It features four main components: 1) A clinical photograph of an eye with a clear cornea. 2) A clinical photograph of an eye with a dark, sclerotic cornea. 3) A clinical photograph showing a blue Intac ring being inserted into a corneal tunnel. 4) A corneal topography chart with three heatmaps and associated data tables. A yellow arrow points from the surgical image to the chart, with the text "10.1 to 2.7 D" indicating the change in Kmetry.

**10.1 to 2.7 D**

**Intacs for ALK Ectasia: Decreased Kmetry and Astigmatism**

This block displays four different corneal transplant techniques in a 2x2 grid. Each technique is shown with a clinical photograph of the eye and a corresponding schematic diagram of the procedure. The techniques are: 1) Sutureless Ant LK, 2) Sutured Ant LK, 3) Deep Ant LK, and 4) Posterior LK (DSEK).

**Sutureless Ant LK**

**Sutured Ant LK**

**Deep Ant LK**

**Posterior LK (DSEK)**

Elegant Transplant Techniques

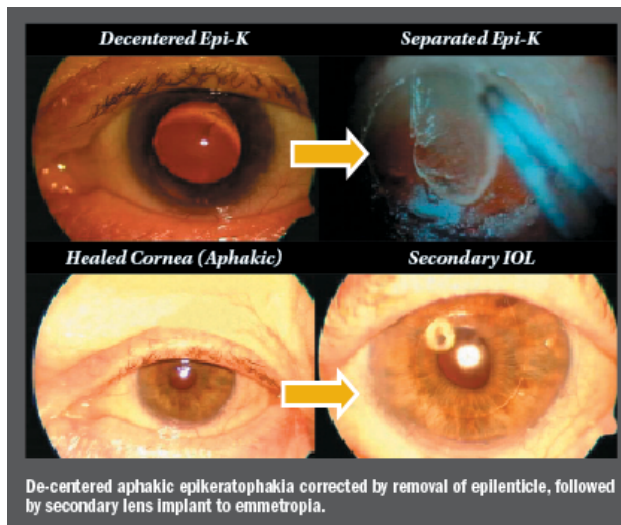
matter how the penetrating transplant is performed—i.e., femtosecond laser, microkeratome, or even a kitchen knife—what matters is how it is put back together (since shape translates to vision and hand stitching of the transplant leads to astigmatism and vision distortion).

Using the 5S system, most corneas that are structurally abnormal, unstable, or compromised should undergo an elegant thought process using Corneoplastique principles (brief, topical, aesthetically pleasing, visually promising) to rehabilitate that cornea with the least interventional approach for that patient and present it as a vision rehabilitative platform for laser PRK surgery.

## Readying cornea for final reshaping

In part 2 of this series, we are reviewing how to repair or prepare the cornea from any situation to present it for final corneal reshaping—straight to 20/20.

Consider a cornea in which the structural instability stems from it being extremely thin and irregular, including deeper levels of scar involvement. Such cases can be elegantly built by imagining that the cornea consists of layers; hence, lamellar keratoplasty in the form of anterior sutureless, anterior sutured, deep anterior lamellar keratoplasty, or posterior lamellar techniques can be performed to rehabilitate the cornea (removing Scar and improving Site) and add donor tissue (plus improving Strength) for future laser reshaping (improving Shape which equals to vision).



By the same token, corneas that are extensively thickened by surgeries, such as epikeratophakia, can undergo removal of the epilenticle to restore the corneal anatomy and present it for final laser reshaping. Physiologically speaking, corneas thickened by Fuch's dystrophy can be rehabilitated using DSAEK/DMEK surgeries to revitalize the cornea to its normal anatomy and thickness for future laser reshaping.

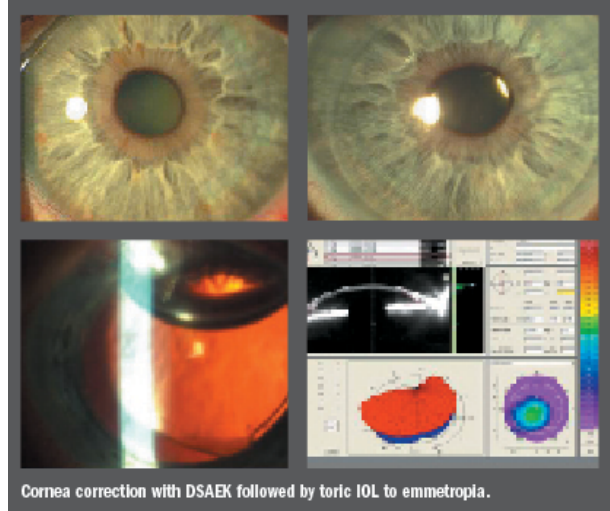
In cases that demand correction of through-and-through corneal anomalies—such as perforation, degeneration, etc.—a penetrating corneal transplant can be suggested as the last resort, and then again, in preparation for future laser reshaping after suture removal

## Best vision potential, emmetropia

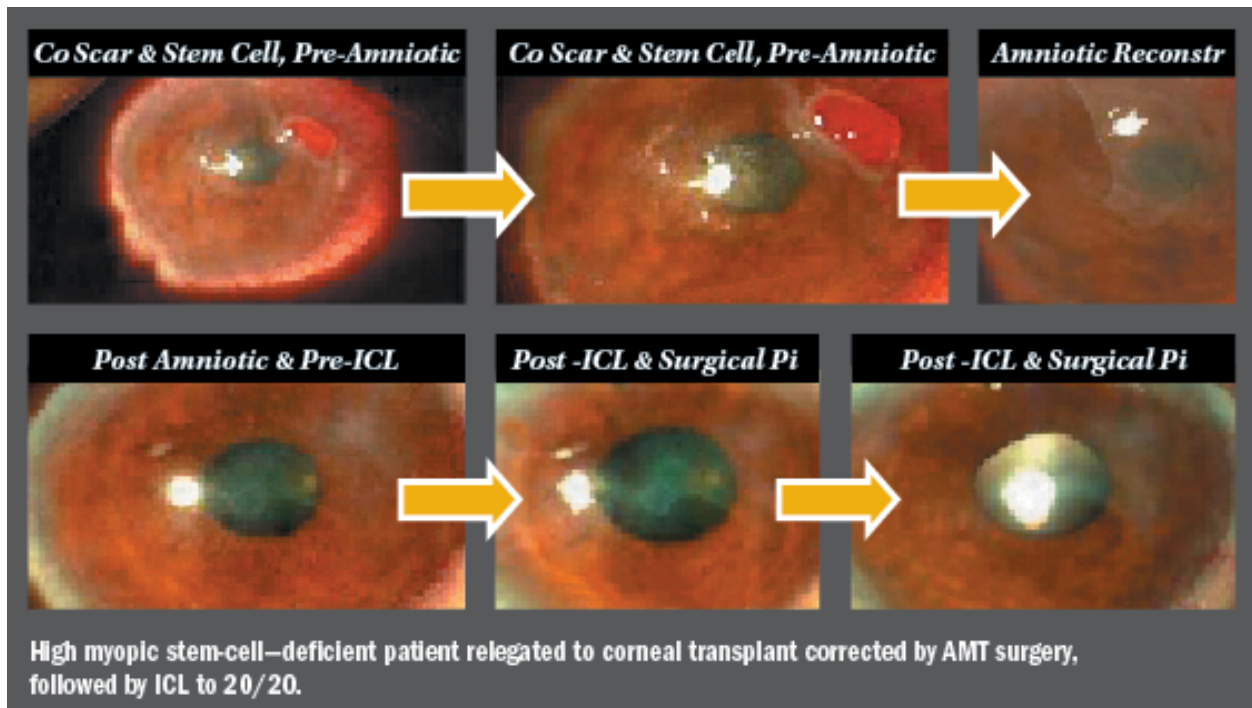
In an aggressive desire to be least interventional, we see this pattern of changing, adding, or removing specific corneal lamellae in a structurally focused fashion to restore normalcy in the anatomy and physiology of the cornea to present it as the most accessible part of the eye in

reshaping it with the excimer laser toward best vision potential (BVP) and emmetropia.

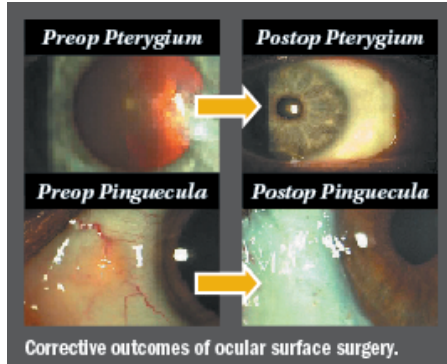
In cases of moderate anatomical abnormality with structural instability (i.e., keratoconus, keratoglobus, pellucid marginal degeneration, or LASIK ectasia), prescription inserts (Intacs, Addition Technology) can be used in an intelligently-applied, asymmetric fashion using different ring combinations (i.e., 0.45 and 0.3), superficial and deep placement, single and paired rings, and incision placement manipulation.



The inserts then act as braces in this unstable cornea, first to correct the progress of the abnormality, and second—in a case-specific, customized fashion—to visually focus the rehabilitated cornea and further present it for laser vision surgery to correct astigmatism, which is the most common error with keratoconus that removes the least amount of tissue with the excimer laser.



Ocular surface pathologies—such as advanced pterygium, recurrent pterygium, limbal lesions—can be addressed with amniotic membrane reconstruction to clear the pathology on the cornea and rehabilitate the ocular surface to present the cornea for vision corrective surgery once again. Not only is it the need of the hour for such amniotic surface procedures to be cosmetically appealing, but also they should be visually propulsive in directing the next step of



corneal reshaping or intraocular optical correction (ICL or premium lens implants) to BVP.

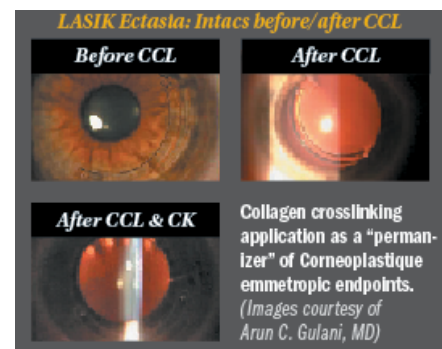
Having rehabilitated the cornea in many of these aforementioned forms, in single or combination processes, collagen cross-linking can be used to “permanize” and stabilize the restored cornea prior to laser reshaping or after laser reshaping.

Intraocular optical manipulations using monofocal, toric, piggyback, or phakic lens implants can be used to emerge with myopic endpoints in preparation for future staged laser

reshaping toward emmetropia and BVP. Myopic laser reshaping corrects the central cornea of the scar, increases the optical zone, smoothens the anterior surface, and also addresses ametropia directly.

In summary, we see how the cornea can be prepared for laser vision surgery and repaired from laser vision surgery, or basically, any kind of keratorefractive surgery coming to its own rescue.

Using the above armamentarium of techniques and technologies, practically every eye deserves a chance toward planned emmetropia using least intervention and visually focused direct techniques, thus presenting the cornea as a vision rehabilitative platform for laser vision correction.



## References

- Gulani AC. *Corneoplastique: Art of vision surgery. Indian J Ophthalmol* 2014;62:3-11.
- Gulani AC. *Using excimer laser PRK—not PTK—for corneal scars: Straight to 20/20 vision. Advanced Ocular Care.* 2012(Sept/Oct);1-3.
- Gulani AC. *Corneoplastique. Video Journal of Ophthalmology.* 2007;22(3).
- Gulani AC. *Corneoplastique system repairs cornea before or after laser refractive surgery. Ocular Surgery News.* 2007 (Nov);25:124-125.
- Gulani AC. “Excimer laser PRK and corneal scars: Refractive surgery to the rescue.” In: *Textbook Mastering Advance Surface Ablation Techniques.* New Dehli, India: JP Publishers;2007:246-248.
- Gulani AC. “Irregular Astigmatism Management in Unstable Cornea.” In: *Textbook of Irregular Astigmatism.* Thorofare, NJ: SLACK Inc. ;2007:251-261.
- Gulani AC. *ART of LASIK surgery: Raising the bar on outcomes and safety.* In: Afshari N, Copeland R, eds. *Textbook of Cornea & Refractive Surgery.* 1st ed. J.P. Publishers; 2012.