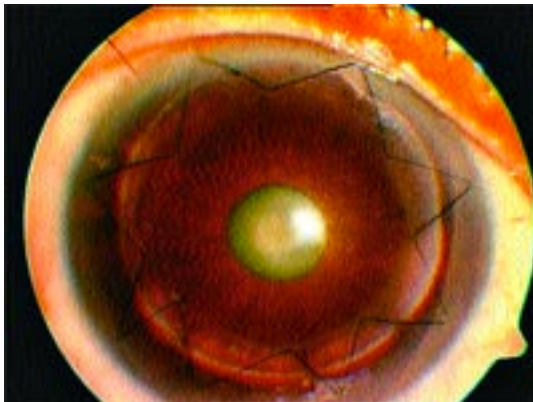


Lamellar corneal procedure useful for reparative surgery

Gloves Off With Gulani by Arun C. Gulani, MD & Lynda Charters



Mastering the lamellar corneal surgery technique may extend the benefits to both physician and patient well beyond LASIK, according to Arun C. Gulani, MD. In the technically demanding surgery, a partial-thickness cornea is replaced with donor tissue of the same size and thickness.

"Lamellar corneal surgery is proving to be especially useful to address the complications arising from LASIK procedures, such as ectasia, as well as the recalcitrant haze or corneal opacities arising from PRK," said Dr. Gulani, chief of cornea external disease, and director, refractive surgery, University of Florida, Jacksonville.

"Patients who have had excessive incisional surgery such as repeated radial keratotomy, which may result in corneal instability, can benefit from lamellar corneal surgery," Dr. Gulani said.

"In special situations, I have even used lamellar surgery for reversals of epikeratophakia."

He described a unique lighting system (Avi Grinblat, New York) he uses to determine the need for lamellar corneal surgery. The lighting design allows him to determine the amount, depth, extent, and the density of the corneal scar tissue.

"In addition to designing the lamellar surgery, another advantage of this lighting system is that it helps me educate patients in a unique fashion," Dr. Gulani said. "When they see their own eyes on a screen, they can understand the opacity and why lamellar surgery, rather than a full-thickness surgery, will benefit them."

Dr. Gulani has also used this lighting system in the operating room, where he shuts off the microscope surgical lights and works toward focused lamellar dissection under this special illumination.

He has also used confocal microscopy to determine the depth of the procedure. Dr. Gulani said that confocal microscopy has an important role in determining the healing patterns both in lamellar surgery and post-LASIK. Before lamellar surgery, he can determine the depth of the opacity and, therefore, the depth of the lamellar replacement. Postoperatively, he can determine how the interface is healing, which applies to LASIK procedures as well. In lamellar refractive

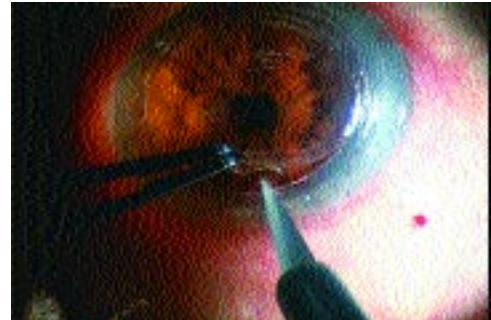
cases such as in epikeratophakia and keratophakia, the corneal interface can be assessed regarding revision surgery.

Dr. Gulani added that he likes to use the Amadeus microkeratome (AMO, Santa Ana, CA) because of its versatility.

"[This] microkeratome not only can be used for LASIK-because of its accuracy and the ability to adjust the hinge, flap size, and thickness to the patient-but also to plan lamellar surgery," Dr. Gulani said.

Figure 1 - Corneal lamellar dissection with special accessory lights (Surgical Specialties Corp., Reading, PA) and the microscope illumination shut off. (Lighting courtesy of Avi Grinblat, New York)

"To circumvent creating a hinge in lamellar cases, I plan for a 9.5-mm cut and use an 8.5-mm ring," he said. "Because the machine is programmed to cut 9.5 mm, it cuts an 8.5-mm circle without a hinge. This eliminates having to cut the hinge later, which might result in a poor edge."



A deeper cut Dr. Gulani said he would like to see a thicker plate for the Amadeus microkeratome that would allow surgeons to perform deeper lamellar surgery. As with LASIK, a cut is made on the cornea and a similar cut on a donor globe.

He emphasized two important points:

The donor thickness always decreases by about 30%.

The size may vary because of the suction in the donor eye.

"The sizes must be modified based on surgeon experience with individual microkeratomes," Dr. Gulani said.

Dr. Gulani also performs the technically demanding hand lamellar surgery and deep lamellar keratoplasty. This is important in the presence of deep scar tissue.



Figure 2 - Corneal scar in the lamellar flap.

"Hand lamellar surgery gives the surgeon the control to go to whatever corneal depth is required," he said. Also, when automated lamellar keratoplasty fails during surgery, one can convert to the hand lamellar procedure to salvage and proceed successfully.

The femtosecond laser is also being used to perform lamellar corneal sections in the donor and recipient, and long-term results are awaited, Dr. Gulani added.

Suturing techniques vary A sutureless procedure can be used when a thin optical automated flap lamellar replacement is performed, especially in young

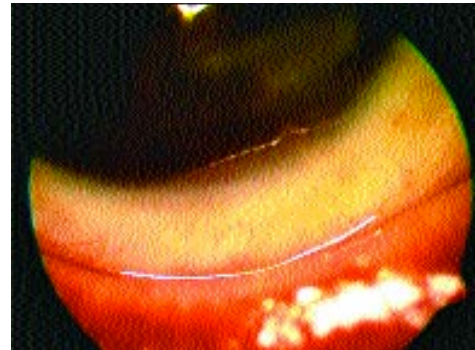
patients in whom the endothelium and the rest of the corneal tissue are normal. Various tissue glues are under investigation, too.

Use of a superficial suture in the periphery of the cornea will produce a trampoline effect to hold the cornea in place. Another option is the Barraquer 8-bite anti-torque stitch to eliminate or decrease astigmatism postoperatively. In deep lamellar procedures, 16-bite stitching must be used to ensure integration of the walls of the lamellar replacement with the cornea.

Dr. Gulani said he is working on a new needle design with Surgical Specialties Corp., Reading, PA, that will simplify suturing even further.

Figure 3 - Patch lamellar graft.

A patch graft "Another very useful application of lamellar surgery is in the form of a tectonic patch graft," Dr. Gulani said. "This has been useful in patients with peripheral corneal disease such as corneal melting associated with rheumatoid arthritis or sites of ocular thinning from various reasons. The corneal patch graft gets fully integrated with the surrounding native tissue." Lamellar surgery can also be performed on the posterior aspect of the cornea in patients with Fuchs' dystrophy in whom the endothelium must be replaced.



Thus, lamellar surgery can replace surface contour and/or tissue strength and stabilize the patient's cornea and clarity. The visual endpoint can then be pursued in a staged manner with surface laser ablation, such as photorefractive keratectomy with mitomycin-C.

"Lamellar corneal surgery is the original starting point for LASIK and also the end point for any complications arising from LASIK. This is why lamellar surgery is so important," Dr. Gulani said. "Most complications associated with LASIK are related to the cornea. If a surgeon can perform lamellar surgery capably, there should be nothing intimidating about LASIK."

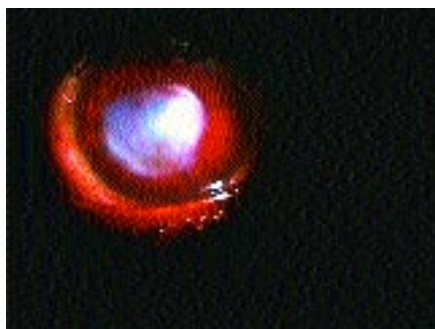


Figure 4 - Clear lamellar corneal transplant postoperatively. Since about 7 years ago, Dr. Gulani has performed a combined corneal transplant by preparing a lamellar periphery and full-thickness central donor button for optimal effect of quick healing (lamellar) and optical quality (penetrating).

To avoid the relatively small risk of expulsive hemorrhage during full-thickness keratoplasties, this procedure results in quick closure and a secure wound with its peripheral lamellar fit into the recipient eye. This is especially advantageous during prolonged corneal transplant surgeries

in combination with vitreoretinal procedures by the retinal service, where Dr. Gulani uses a temporary keratoprosthesis.