

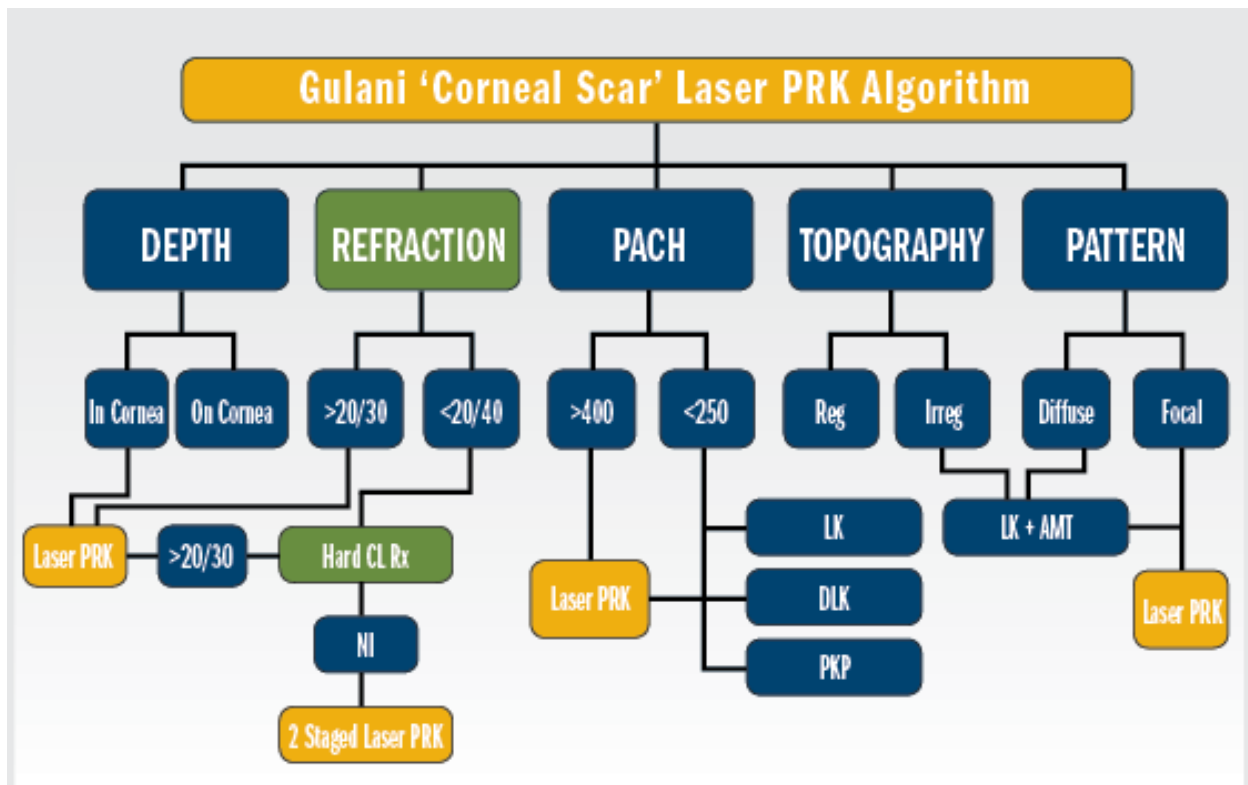
## Decoding corneal scars: Straight to 20/20

*Gloves Off With Gulani by Arun C. Gulani, MD*

My desire in these invited columns is simple—to change ophthalmologists' mindset! To free eye surgeons from the burden of technology and terminology.

When looking at a corneal scar, our inherent mindset is: "There is the culprit. Let's eradicate it." Numerous diagnostic technologies are then deployed to "understand the scar and its obviously criminal impact on vision."

Then—in their minds—many ophthalmologists go through an elegant and complicated thought process to determine whether to choose laser PTK (an optically incorrect surgery), diamond burr application (a barbaric procedure on an elegant visual organ), or a corneal transplant (a relatively interventional procedure that should be the last resort, very much like having to open the entire abdomen to get to the gall bladder) as the correct treatment for this corneal scar.



The refraction is the mainstay of the corneal scar algorithm, where vision better than 20/30 suggests straight laser PRK and where vision less than 20/40, following a hard contact lens trial, can determine staged laser in two stages or a scar peel, followed by myopic ablation.

What I suggest instead is to look at the corneal scar and ask yourself, “How can I use this or modify this to help the patient see better with the least intervention?” and “Is it necessary to remove this and at what cost?”

By cost, I mean, the cost in “vision” currency. Chasing the scar at the cost of vision is not acceptable.

In this article focusing on corneal scars, I will explain my concepts of addressing anterior corneal scars with laser PRK (not PTK) straight to 20/20. In part 2, I shall explain how to build the cornea with various modalities in presenting it for laser PRK.

Anterior corneal scars affect vision directly by blocking the optical pathway and indirectly, by altering the shape, and hence the refractive status. Using “Corneoplastique” principles, we can use these very factors and reverse them to our advantage.

In the Gulani 5S algorithm, you can see the impact of the corneal scar on vision and determine the patterned approach of corneal rehabilitation and laser or direct laser, and straight reshaping to vision. The refraction is the mainstay of the corneal scar algorithm, where vision better than 20/30 suggests straight laser PRK; whereas less than 20/40, following a hard contact lens trial, can determine staged laser in two stages or a scar peel, followed by myopic ablation.

For the sake of simplicity, I have divided corneal scars into “on-cornea” scars, which are above the Bowman’s membrane and lead to a camouflaged topography and misleading refractive error and “in-cornea” scars, which actually become part of the cornea and are directly responsible for the topography, and have a direct correlate to the refractive error. These can be lasered through.

Instead of laser PTK, which chases the scar and distorts the shape (costing us in vision currency), why not reshape the cornea and take it straight to vision (in many cases, despite a residual scar)?

For example, one of my patients (see related video) presented with a case of dense corneal scar following herpetic infection 20 years ago. You can see the circular light reflex from the excimer laser seen as D-shaped, due to high astigmatism. After removal of epithelium and confirming “in-cornea” status (herpetic scars usually become part of the cornea, thus producing a smooth surface once the epithelium is removed), I proceeded with a refractive laser ablation, and then applied mitomycin-C for 30 seconds to the central cornea. Upon application of balanced saline solution, the light reflex had become circular, which translates to vision. This patient ended with uncorrected vision of 20/25+ and was thrilled with her outcome.

### ***On-Cornea and In-Cornea Scars***

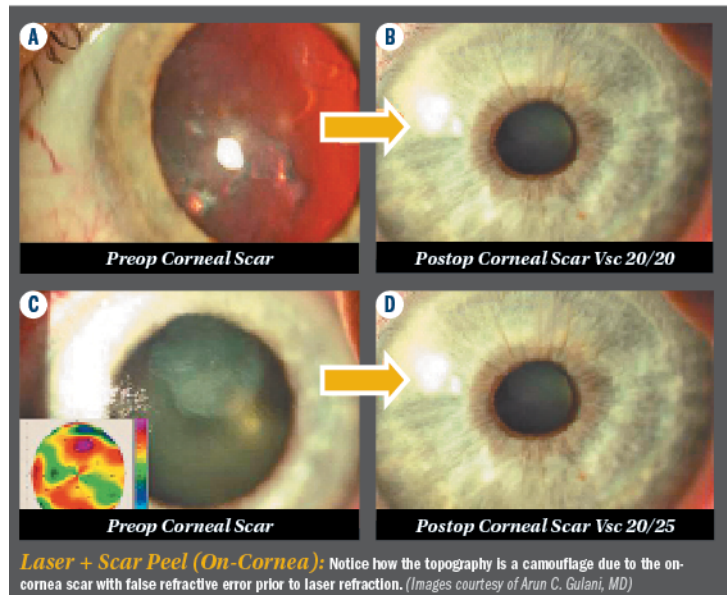
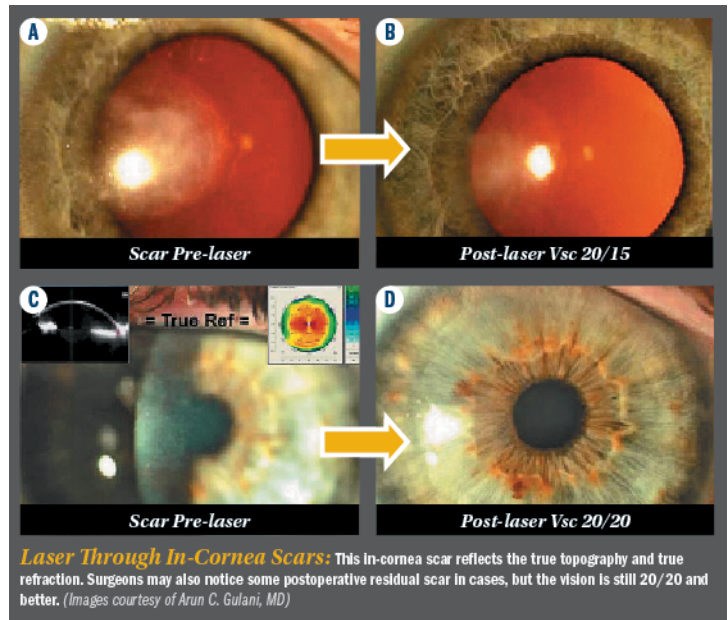
On-cornea scars can be peeled off right under the laser using the cornea as what I call a “resistance-guided platform” which is comprised of pulling on the scar, making sure you remove it completely, in one piece, using the rest of the cornea as your resistance platform. This is followed by refractive PRK (always with mitomycin-C application) as single stage or myopic

PRK to be followed by stage two for refractive PRK to emmetropia.

Deeper on-cornea scars can also be peeled off using patience and a resistance-guided technique as well to peel them gently off of the rest of the cornea. Once again, try to maintain the entire piece as a single removal technique. Once it clears the visual axis, you can proceed with refractive laser PRK ablation, followed again by the application of mitomycin-C. This can result in complete central clarity, to an excellent outcome.

In this particular case, as seen in the video, the patient's on-cornea scar was peeled off gently using the cornea as a resistance guided platform followed by myopic laser application with mitomycin-C for 20 seconds, resulting in an outcome of 20/20- uncorrected vision.

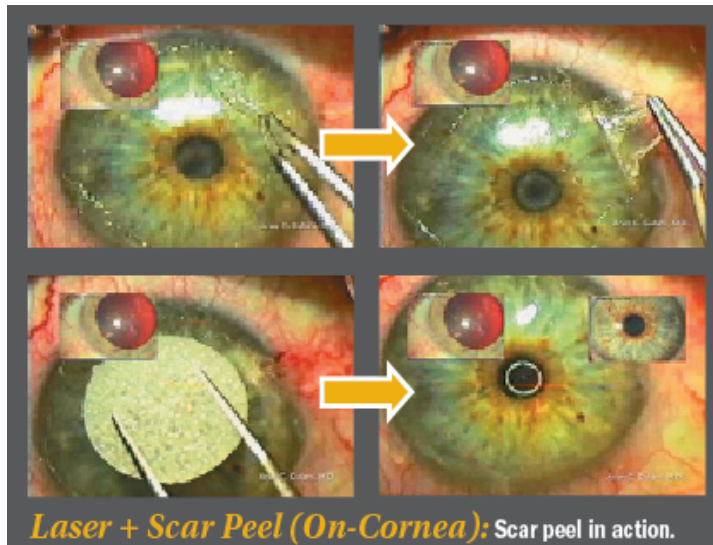
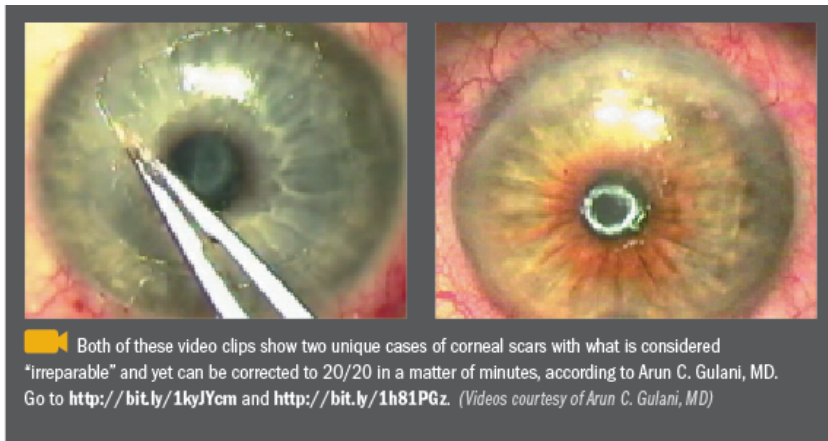
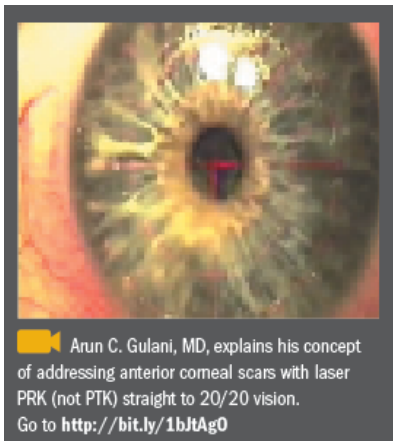
In summary, in-cornea scars can be lasered directly in the PRK mode, shaping the cornea, and indirectly removing the scar, straight to a visual outcome. In cases of on-cornea scars, the scar can be gently peeled off, maintaining all the principles we discussed about using the corneal platform as a resistance guided technique in lifting the entire scar gently, in full completion, off the remaining cornea. This is followed by laser PRK with mitomycin-C and a bandage contact lens to reach tremendous visual outcomes (single or two-staged).



Intraocular optical manipulation in the form of lens based (pseudophakic and phakic implants) techniques can be combined to aim for myopic PRK before or after as second stage (the endpoint always being emmetropia, with an indirect goal of scar removal).

No matter how bad the scar looks, let us use our algorithm to insist on taking patients straight to vision, with the most elegance possible, maintaining the principles of "Corneoplastique" surgery —topical, brief, aesthetically pleasing, and visually promising.

Refractive laser PRK surgery—when practiced as an art—not only can address virgin eyes with all levels of ametropia, but also reverse and correct complex as well as complicated cases with corneal scars back to 20/20 vision. Refractive surgery truly then can come to its own rescue!



## References

Gulani AC. Using excimer laser PRK—not PTK—for corneal scars: Straight to 20/20 vision. *Advanced Ocular Care*. 2012(Sept/Oct);1-3.

Gulani AC. Combined corneal scar excision, laser PRK surgery seeks unaided emmetropia. *Ocular Surgery News*. June 20, 2008. <http://www.healio.com/ophthalmology/cornea-external-disease/news/print/ocular-surgery-news/%7Bc9f4a51f-cba8-472c-afc9-0d688d30a7cc%7D/combined-corneal-scar-excision-prk-surgery-seeks-unaided-emmetropia>.

Gulani AC. Corneoplastique system repairs cornea before or after laser refractive surgery. *Ocular Surgery News*. 2007;25:124-125.

Gulani AC. "Excimer laser PRK and corneal scars: Refractive surgery to the rescue." In: *Textbook Mastering Advance Surface Ablation Techniques*. New Delhi, India: JP Publishers. 2007;246-248.

Gulani AC. "Irregular astigmatism management in unstable cornea." In: *Textbook of Irregular Astigmatism*. Thorofare, NJ: Slack Inc.;2007:251-261.

