

## Staged cataract surgery: Art of optimization to individual outcomes

How to apply the inside-out and outside-in techniques to move toward emmetropia

*Gloves Off with Gulani by Arun C. Gulani, M.D., M.S.*

*In this second part of a three-part column on approaches to cataract surgery, the spotlight is on staged cataract surgery. Cataract surgery is an opportunity and avenue to manipulate the internal optics of the eye because the cataract (lens) itself is a powerful and important optical element.*

*Taking full advantage of this opportunity, which is a once-in-a-lifetime event for the patient, adjusting the internal optics allows surgeons to design our patients' individual outcomes as a single or staged goal.*

*Therefore, with the inside-out staged concept, cataract surgery is performed with the goal of arranging the inner optics of the eye to result in a final optical endpoint that appropriately presents the cornea as a vision rehabilitative platform for correction by laser vision surgery. Therefore, the internal surgery is performed first (cataract surgery) followed by external corneal surgery. This obtains the best vision potential and designed refractive endpoint for each eye.*



*Having performed numerous permutations and combinations, I have summarized staged cataract surgery into two simple strategies: Inside-out and outside-in staged surgery.*

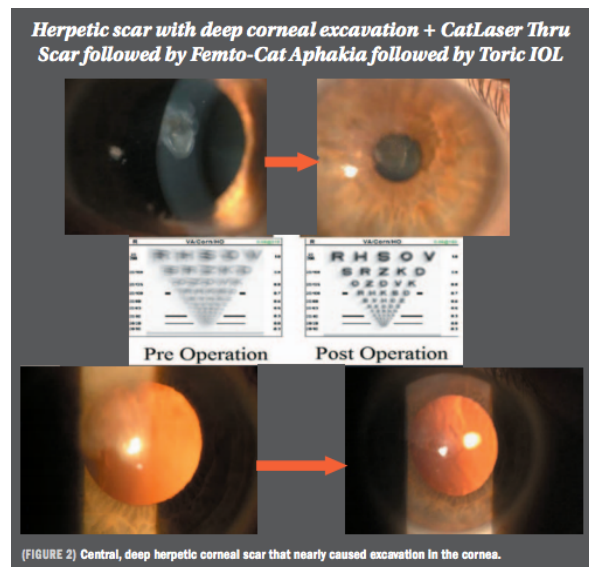
### **INSIDE-OUT STAGED CONCEPT**

*To put it simply, the inside-out approach in most cases has a potentially measureable cornea (to determine the IOL placement presents the refractive endpoint for the most needed laser ablation profile, i.e., myopic/hyperopic (PRK mode) to then correct the corneal pathology as well as result in emmetropia simultaneously.*

*the IOL placement presents the refractive endpoint for the most needed laser ablation profile, i.e., myopic/hyperopic (PRK mode) to then correct the corneal pathology as well as result in emmetropia simultaneously.*

Therefore, with the inside-out staged concept, cataract surgery is performed with the goal of arranging the inner optics of the eye to result in a final optical endpoint that appropriately presents the cornea as a vision rehabilitative platform for correction by laser vision surgery. Therefore, the internal surgery is performed first (cataract surgery) followed by external corneal surgery. This obtains the best vision potential and designed refractive endpoint for each eye.

For example, in a patient who has undergone RK, cataract surgery can be performed with the goal of achieving hyperopia (in very flat corneas) and followed with laser PRK to steepen the cornea and improve the optical status.



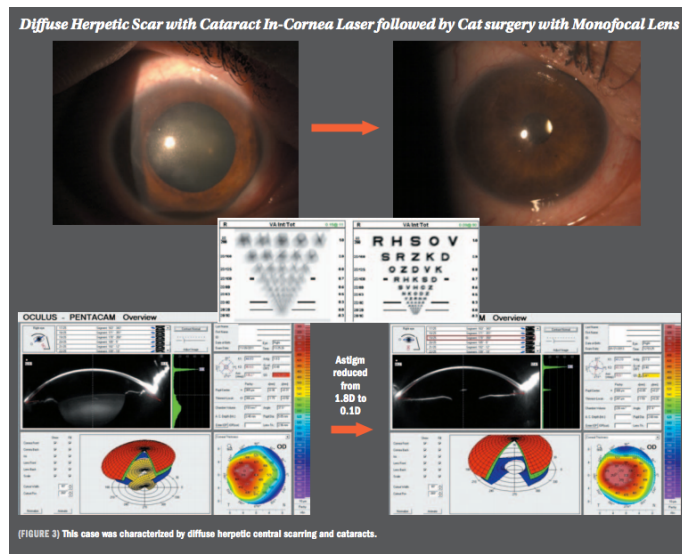
In some cases of steep corneas, flattening of the cornea may be the optimal endpoint and hence cataract surgery could be designed for myopic endpoint accordingly.

This inside-out approach also can be used in cases with a corneal scar to first result in myopic astigmatism from cataract surgery and then followed by laser in PRK mode (Corneoplastique), to both repair the scar and achieve a clearer cornea and reach emmetropia.

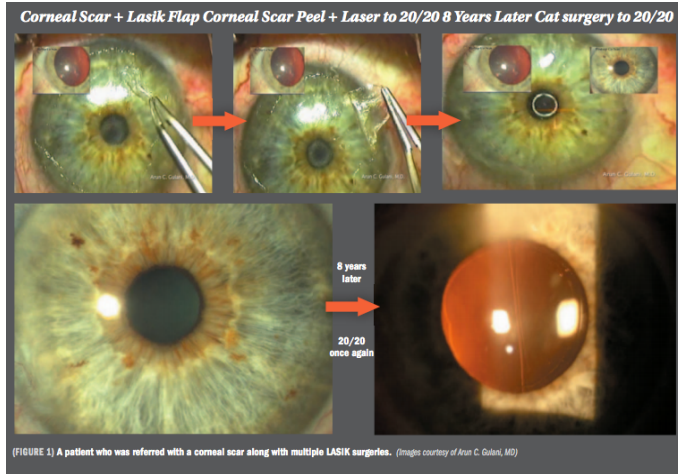
### OUTSIDE-IN APPROACH

Conversely, the outside-in approach can be used in patients in whom the corneal status

prevents accurate IOL calculation or when the corneal status is a hindrance to safe, planned cataract surgery. These poorly measureable or scarred corneas need to be corrected (Corneoplastique as described in previous columns) with various modalities, such as Intacs



(Addition Technology)/amniotic graft/lamellar graft/laser Corneoplastique, etc., and then with this measurable cornea, we proceed to the final internal IOL placement (cataract surgery) toward emmetropia.



Using this approach, for example, in cases of LASIK ectasia, an Intacs segment can be implanted to stabilize and flatten the cornea and bring it to a measurable state at which time an accurate IOL can be implanted for optimal emmetropic vision.

This approach also can be applied to patients with corneal scars after RK. The corneal scar can be peeled, leaving a measurable cornea followed by accurate lens implantation during cataract surgery. Lamellar keratoplasty can be performed in a very thin scarred cornea (Gulani 5S system), and the cataract then can be

removed through a clear cornea for a myopic outcome to be followed by central ablation myopic laser to result in a regular, clear, and emmetropically neutral endpoint.

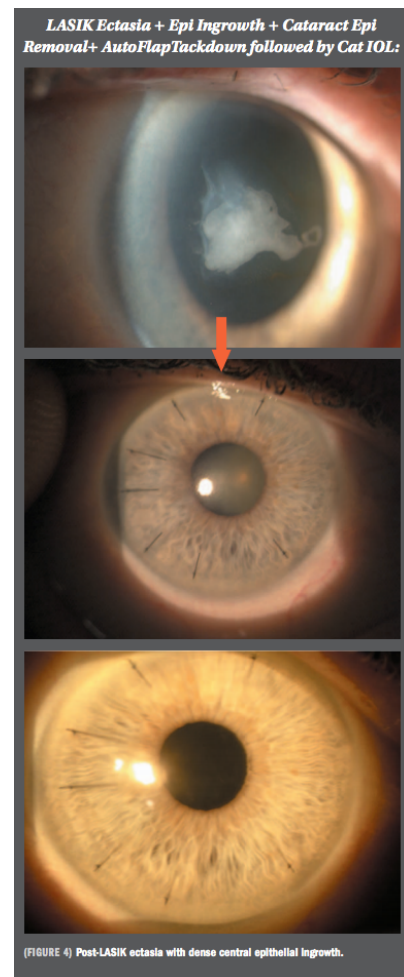
In every case I work on, my 5S system works as my mental “coin sorter” to allow me to use over 50 different refractive surgery techniques to then be combined with unlimited permutations of technology while respecting all of my Corneoplastique principles (elegant, brief, topical, least interventional, and visually promising).

#### PATIENT/SURGEON TEAM

In my more than 20 years of experience with this designed, staged concept, I have seen our patients’ enthusiasm as I explain my plan to bring them to an optimal level of vision. The patients become my team member, which is a welcome side effect of the planning, and they express their excitement as we go from one stage to the next.

The first stage has already improved the vision to a point at which they become even more confident about embarking on the second stage.

At the end of the second stage, they are amazed that they were told previously that nothing could be done to improve their situation. As I alluded to previously, my 5S system breaks down a seemingly unapproachable problem into a series of smaller very approachable procedures, i.e., the impossible becomes possible, and unfolds in front of you.



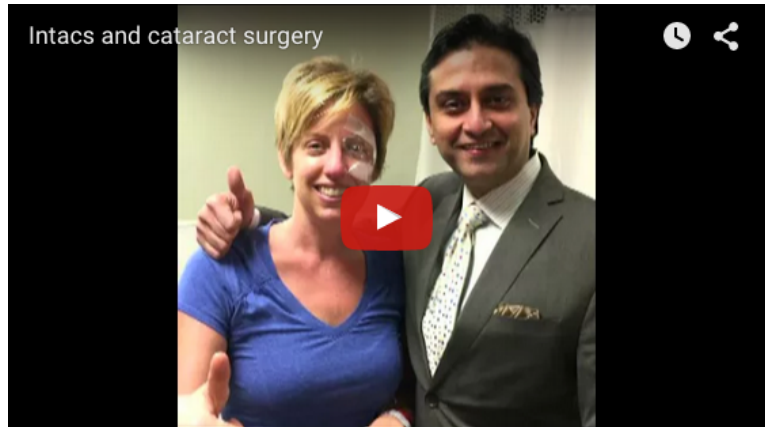*The key factor here is never to forget that every action of ours should be in the patient's best interest and our mindset should be unrelenting as we aim for emmetropia.*

*By using these concepts, almost any situation can be addressed and worked on by the inside-out or outside-in technique to move toward emmetropia without performing highly interventional, painful, debilitating procedures. At the same time, the ocular integrity is well preserved and stable.*

*Challenging cataract surgeries approached in a staged fashion can be used not only to design vision as mentioned in Part 1 of this column, but also to optically manipulate the interior of the eye to present stage 2 as the final refractive surgical component—reaching the end zone and keeping all the principles intact with the welcome side effect of having the patient become cheerleader as you reach the end zone.*

## NOTEWORTHY CASES

*The next column will highlight numerous case scenarios of patients who were considered to be complex cases referred to me from around the world. I will outline with images and videos my thought process and journey toward their best vision potential using the outside-in and the inside-out approaches. Until then, here are a few case studies to whet the appetite:*



*Case 2 (slide 2) is that of a patient who was referred with a corneal scar along with multiple LASIK surgeries. This scar was peeled along with simultaneous laser. The patient had 20/20 vision for 8 years when age-related cataracts developed. Following cataract removal recently, the patient again has 20/20 vision.*

*The patient in case 3 (slide 3) had a central, deep herpetic corneal scar that nearly caused an excavation in the cornea with best corrected 20/400 vision. Following "In Cornea" Laser approach he had a moderately smooth cornea, such that the patient was satisfied with the uncorrected 20/40 vision. Later, when an age-related cataract developed, given the complex nature of the cornea with poor visibility and difficult calculation, I used a femtosecond laser to perform a perfect rhexis in preparation for an aphakic staged technique to then perform toric IOL placement as a staged process 1 week later following accurate aphakic refraction (with an acknowledgement to Richard Mackool, MD) to an excellent end point of 20/25.*

*Case 4 (slide 4) was characterized by diffuse herpetic central scarring and cataracts. Because the lens power was difficult to measure, I applied laser to the cornea through the scar that resulted in good clarity and a measurable cornea. This was followed by cataract surgery and implantation of a monofocal lens to achieve emmetropia. In this case, the laser corrected the previous astigmatism and cleared the cornea before cataract surgery.*

*In case 6 (slide 6), the patient had post-LASIK ectasia with dense central epithelial ingrowth. I lifted the LASIK flap and the epithelial ingrowth was removed. The LASIK flap was tacked down like a lamellar keratoplasty and anchored with selective topo-guided sutures. After this, the cornea was measurable and once stability was determined, cataract surgery was performed and an excellent visual outcome was achieved.*

## **References**

- *Gulani AC. Femtosecond Laser in Refractive Lens Exchange: Surgical Treatment for Presbyopia. Wang M, ed.; Slack Inc., Thorofare, NJ); 2016;109-115.*
- *Gulani AC. Corneoplastique: Art of LASIK & cataract surgery. Ind J Ophthalmol 2014;62:3-11.*
- *Gulani AC. Evaluating the impact of femto laser-assisted capsulotomy. Cataract Refract Surg Today Europe 2014;9:36-50.*
- *Gulani AC. Shaping the future and reshaping the past: the art of vision surgery. Chapter 98. In: Copeland and Afshari's Principles and Practice of Cornea. New Delhi, India: Jaypee Brothers Medical Publishers, 2013;2:1252-73.*
- *Donnenfeld E, Gulani AC. Astigmatism correction during cataract surgery. In: Garg H, Alió JL, eds. Femtosecond Laser: Techniques and Technology. 1st ed. Miami; JayPee Highlights Medical Publishers; 2012;21:155-161.*
- *Gulani, AC. Vision à la carte: Designing vision. Ophthalmology Times. 2013;38:31-33.*
- *Gulani AC. Corneoplastique. Techniques in Ophthalmology 2007;5:11-20.*