

Ophthalmology Times

CUTTING-EDGE ADVANCEMENTS

Premium cataract surgery: Correcting complications and side effects

Keys to unfolding the specific surgical plan of action

by Arun C. Gulani, M.D., M.S.

This designing cataract surgery series addresses methods to correct complications and side effects of premium cataract surgery, including patient dissatisfaction postoperatively.

For simplification, I have devised a classification system based on more than two decades of correcting complications associated with cataract surgery in patients from around the globe and categorized the system for simplicity in understanding the core issue—patient perception of the problem—and thereby unfolding the specific plan of action.

Gulani Cataract Complication Analysis: I. Surgery related complications

- a. Anatomic-like corneal damage, iris damage, etc.
- b. Inflammation
- c. Optical pathway (i.e., pupil, lens centration, etc.)

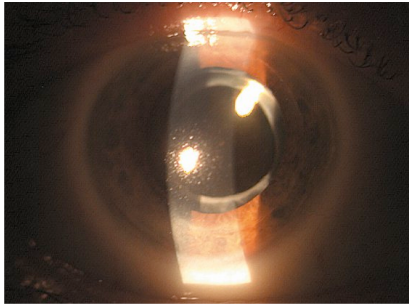
II. IOL-based problems

- a. IOL power
- b. IOL optics in relation with corneal optics
- c. IOL defects (broken/cracked/subluxed)

III. Patient symptomatology and dissatisfaction

- 1. Dysphotopsia (IOL capture)
- 2. Glares/haloes, etc.
- 3. Psychological

I. Surgery-Related Complications



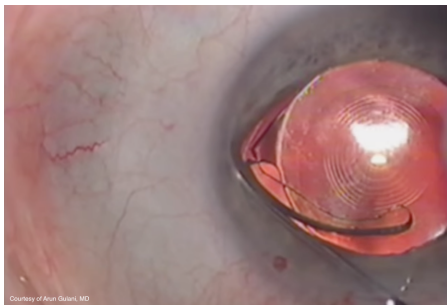
Complications associated with cataract surgery can be linked to the surgery itself in that the surgery can have resulted in anatomic damage in the corneal, iris, or vitreoretinal tissue. There may also be combinations of these directly or indirectly.

Additionally, surgery can cause inflammation that can decrease the visual outcomes, i.e., cystoid macular edema, and even involve adjacent anatomy-related optical pathway like decentration of the lens implant relative to pupil centration and thus the resultant visual symptoms. When the vision is impacted negatively, this in turn affects patient satisfaction.

Anatomic damage can be corrected in the appropriate sequence, as I described in previous columns, keeping in mind the least-interventional Corneoplastique techniques for restoring the anatomy in planning for the optimal optical outcome.

Inflammation can be appropriately and aggressively treated to resolution while optical pathway incoherence can be addressed in pupil-IOL relations with many approaches, the most minimal of which could be the Donnenfeld Argon Iris Laser (at the site of the decentered pupillary edge) technique.

II. IOL-based complications



visual quality.

These problems can be related to defective IOLs, such as broken haptics and damaged optics, which resulted from a manufacturing issue or from handling before or during surgery (while loading or manipulating the lens). In such cases, an IOL exchange can be performed safely to restore the

Poor vision also can result from a less-than-optimal choice of IOL based on determining the angle kappa, spherical aberrations levels, refractive errors, and corneal irregularities and not matching them with the correct optic of the appropriate IOL.

Further, the IOL implant often may be incorrect in its emmetropic outcome, in that the patient may be over-corrected or under-corrected with or without associated astigmatism.

Keeping Corneoplastique principles in mind, the IOL can be exchanged for another properly calculated IOL or a laser surface ablation technique or a piggyback technique performed as previously described in stage-2 surgeries to achieve an optimal optical endpoint.

III. Patient symptomatology and dissatisfaction

In some cases, patients may not have been adequately educated about and prepared for the visual outcomes, which the surgeon may deem to be perfect. In addition, the surgeons'

March 01, 2016

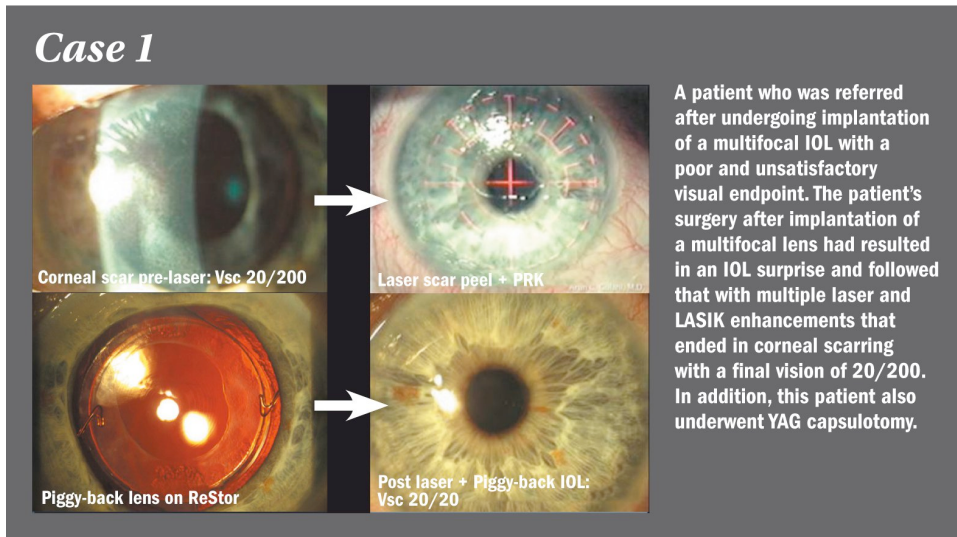
anticipated desires and profession-related endpoints and other confounding factors may negatively impact patient satisfaction postoperatively.

Some patients can be negatively or psychologically affected or unprepared for improper or unexpected endpoints such as glare and halos. They may find relief only with exchange of the IOLs.

Case scenarios

These case scenarios represent the application of logic-based principles of Corneoplastique, in applying the least interventional, brief, topical, elegant, and visually promising techniques to achieve the best visual potential (BVP) while striving in most cases to honor the original surgeon's standing and choice of technology.

Case 1 was that of a patient who was referred to me after undergoing implantation of a multifocal IOL with a poor and unsatisfactory visual endpoint. The patient's surgery after implantation of a multifocal lens had resulted in an IOL surprise. It followed with multiple laser and LASIK enhancements that ended in corneal scarring with a final vision of 20/200. In addition, this patient also underwent YAG capsulotomy. The patient was extremely angry with her surgeon and concerned as a result of the surgeries and poor visual outcome.



Following my 5S system, I first wanted a “measurable” cornea and hence performed laser PRK (on-cornea scar) to correct the scarring and achieved a

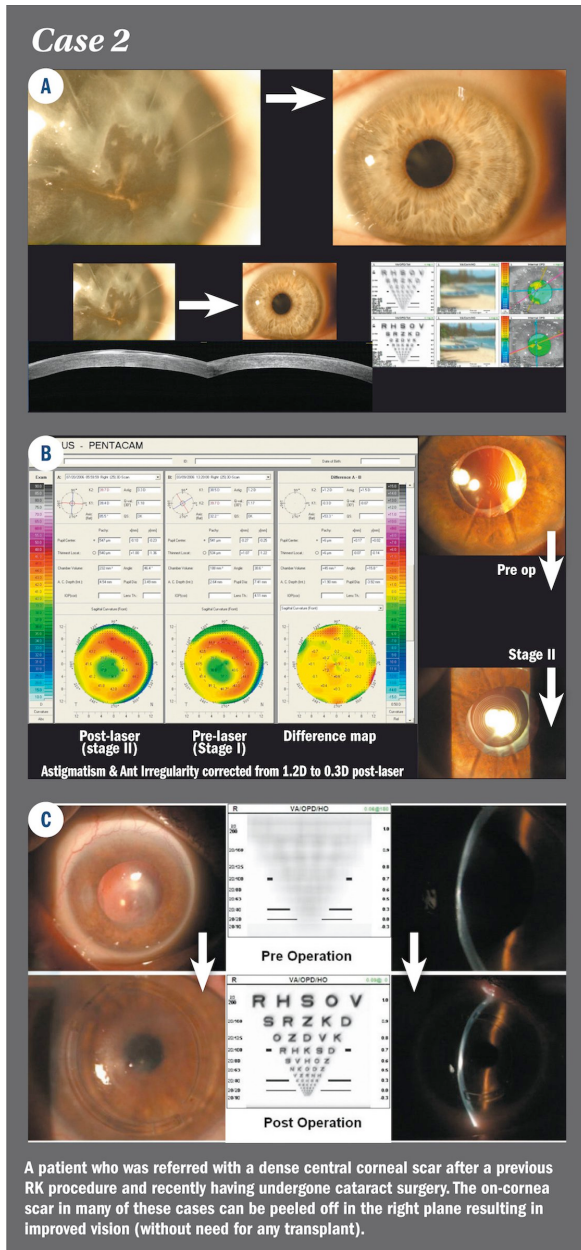
clear measurable cornea that refracted to a hyperopic endpoint of +6.00 diopters with best-corrected vision of 20/25.

Now, as planned, I was aiming to correct this measurable and accurate refractive error so a lens-based correction was the path that I zeroed down to. Considering the fact that this patient had undergone a YAG capsulotomy and therefore this lens implant could not be exchanged without detrimental maneuvers, I planned a piggyback lens implant (the Corneoplastique principles were maintained: brief, topical, aesthetically pleasing, least interventional, and visually most promising) and brought this patient to 20/20 unaided for distance and near vision.

Case 2

Case 2 was that of a patient who was referred with a dense central corneal scar after a previous RK procedure and recently having undergone cataract surgery. The on-cornea scar in many of these cases can be peeled off in the right plane resulting in improved vision (without need for any transplant) and he was already pleased with his vision so much that he deferred the planned laser corneal advanced surface ablation surgery (ASA) to emmetropia.

Another patient was referred by his eye surgeon following implantation of an accommodative IOL in an eye treated previously with RK. Before a knee-jerk reaction of exchanging the implant, I always look at refractive errors and offer simulation to look for symptomatic improvements (BVP).



Once the ocular surface is corrected, the refractive errors can be addressed using surface laser ASA (the new-carpet-over-broken-tiles approach) and achieve visual satisfaction.

March 01, 2016

Most patients with RK—and for that matter any previous corneal surgeries who have bad endpoints after multifocal and premium IOL implants—usually have some residual refractive error, most often astigmatism.

I encourage surgeons to make sure that the refractive endpoint is always neutral before blaming the IOL implant. These cases can be corrected easily with corneal refractive surgery to excellent endpoints, thus maximizing the impact of the premium lens implant to achieve optimal vision.

Case 3

Case 3 was that of a patient referred to me who had undergone a multifocal lens implant with her surgeon and she was unhappy with her vision. I include this case to demonstrate the psychological impact on patients, because I do not succumb to a

knee-jerk reaction to remove an IOL and blame the previous surgeon unless I have run out of my mental thought process of salvaging vision with that IOL before embarking on any surgery.

After treating her obvious dry eye, I refracted her and determined her astigmatism to be stable, and on simulation she found improvement in her vision with that correction. We then proceeded with laser post vision surgery and she was now 20/20 in this eye.


She noticed improved vision but came back to me with her husband saying she was still angry at her previous surgeon for not explaining haloes and glare that could occur with this lens implant and hence wanted it removed. The interesting factor in this case is she had no such symptoms even on subjective testing and simulations and she herself admitted to not really having the symptoms described in a Google search.

After an extensive discussion with me and her husband, she understood how much her vision had improved and that she had no such symptoms which she had read online about. She called me twice and we had lengthy conversations and every time she agreed that she was just paranoid it can happen to her and would thank me for her improved vision of 20/20.

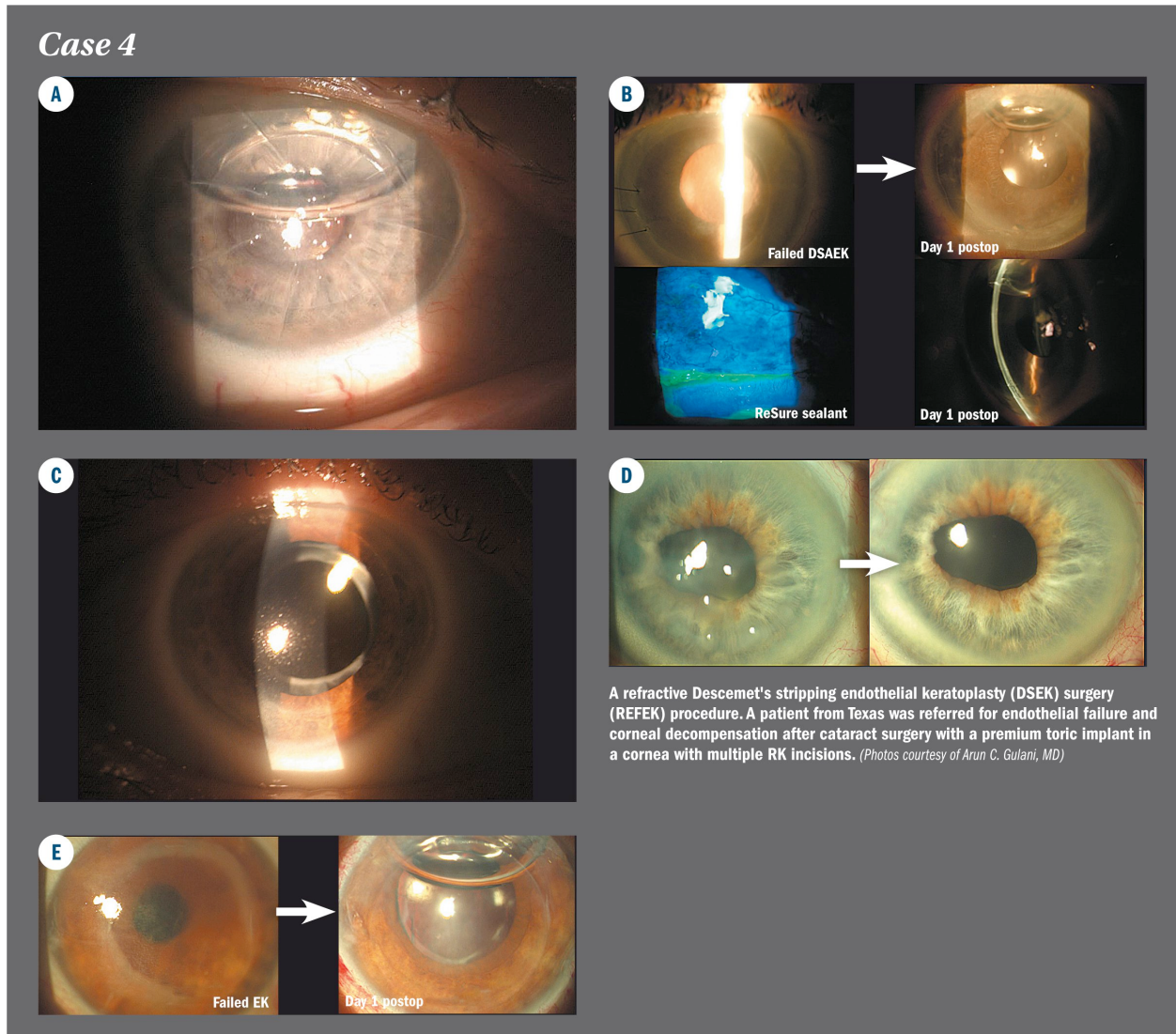
A month later she called again and said she had determined to have this lens implant removed. It was, she described, “agonizing” for her to live with something that could cause symptoms that she read about online and her surgeon should have at least educated her, let alone warned her.

She travelled back to me and after another detailed consultation (during which she explained her agony) and informed consent (remember she was 20/20 now) I agreed to remove her multifocal lens and maintain her 20/20 vision using a monofocal lens implant. The next day after surgery she was 20/20 and very happy and relieved.

An example of a case where psychologically a patient can actually feel so traumatized by what she felt was a “time-bomb” in her eye just because of her anger toward her surgeon. A lawsuit was averted and relations corrected.



Case 4



Case 4 was that of a 60-year-old patient with keratoconus who underwent implantation of a monofocal IOL with his surgeon a couple of years previously and then sought my consult for his poor resultant vision of 20/200.

On presentation, he had a well-placed monofocal lens implant, deep anterior chamber, open posterior chamber with healthy endothelium, and keratoconus with hyperopia and astigmatism along with steep keratometry and anterior corneal scarring.

March 1, 2016

Following my 5S system, I wanted to correct the following issues: hyperopia, astigmatism, central scarring, and high keratometry.

The single surgery that could correct all of these is myopic-astigmatic laser ASA, so in order to perform that surgery, I first had to make his refraction myopic with a planned piggyback IOL and after 1 month measured him and proceeded with laser ASA in myopic mode to correct his refractive errors while flattening his keratometry and clearing the central scar (in-cornea scar) as a welcome side effect to unaided 20/20 vision.

His vision worsened after piggyback IOL implantation as planned since optical end point was my goal not vision and then we took him from there straight to 20/20 vision.

Thus, we made his own lens implant work and honored his surgeon's desire and corrected their relation and trust in each other. This patient now has pursued his once lost passion—to fly!

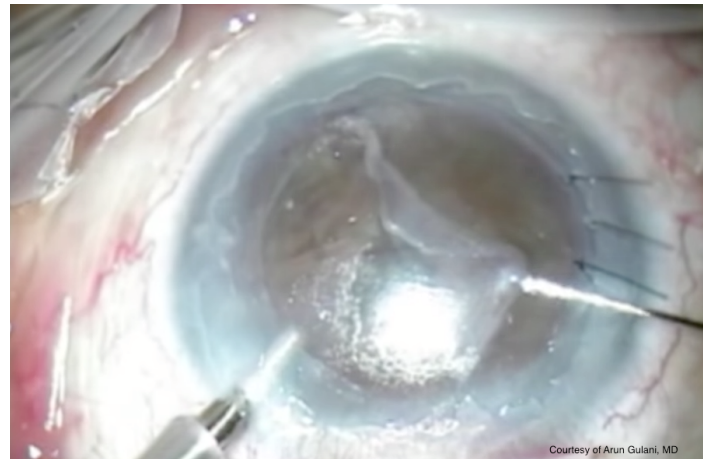
He excitedly emailed me just this week with the news that he recertified his license to fly and is 20/20.

Case 5

Case 5 was that of a REFRACTIVE Descemet's stripping endothelial keratoplasty (DSEK) surgery (REFEK) procedure. A patient from Texas was referred for endothelial failure and corneal decompensation after cataract surgery with a premium toric implant in a cornea with multiple RK incisions.

Here again, leaving the patient's toric IOL in place and following my 5S system, my only desire was how to maintain her own cornea (of course deep anterior lamellar keratoplasty/penetrating keratoplasty was a back-up option and part of informed consent) despite the RK since there was history of improved vision close to emmetropia after her cataract surgery before eventual corneal decompensation.

I planned on performing my modified Descemet's stripping automated endothelial keratoplasty (DSAEK) technique (Gulani single instrument DSAEK) trying my best to avoid sutures and also keep my surgery as non-invasive as possible with thin graft,



March 1, 2016

focused centration and secure incision. My goal was to restore her potential vision with minimal distortion of vision due to the surgical procedure. This goal was achieved successfully as I named this technique REFEEK or REFRACTIVE DSEK surgery) for future similar situations, which involved a central small diameter endothelial graft and sutureless incision.

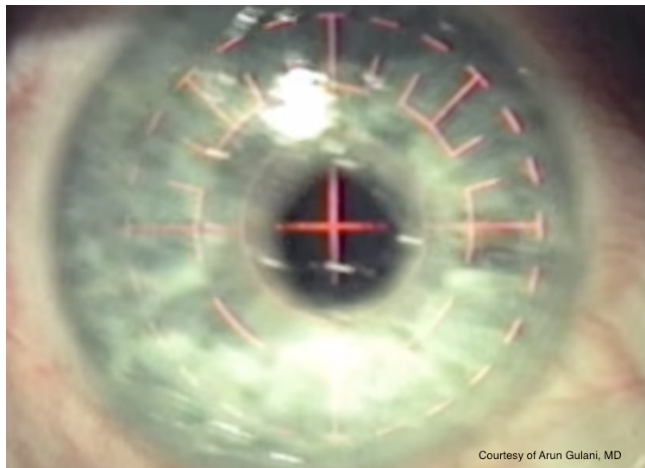
Many such examples can be seen where you can work refractively with visual impact either to enhance or at least maintain emmetropic vision while corrected corneal disease. In some cases,

March 01, 2016

I use ReSure sealant (Ocular Therapeutix, Inc.) to further secure their incisions especially in patients travelling back to their surgeons.

Case 6

Case 6 was my own patient who sought my services for cataracts associated with bitemporal, elevated scars on her corneas with high irregular astigmatism of nearly 5.8 diopters and topographic distortion. Contact lenses were not possible because of patient discomfort and the irregular corneal shape.



I usually always work on such a cornea first to make it measureable and then proceed with cataract surgery, but she was a young school teacher and could not take that much time off work (four

elevated scar-ptygium complexes/lesions, one on each side of her corneas) and so I relented and proceeded with refraction like I always do and for some reason (also because the IOLMaster (Zeiss) could not measure her axial length/Ks or IOL powers) in this case I did not believe her astigmatism and its high correlate given her improving to

March 1, 2016

20/70- with my refraction, my plan therefore being to perform laser ASA as a staged procedure to get her to emmetropia after cataract surgery.

On performing her cataract surgery, I came to my end zone of plano spherical error despite poor reliability of her automated calculations but when I saw her astigmatism to actually be the nearly 6 diopters that was measured by me at all levels (though inconsistent) preoperatively, I could improve her vision even more. Now, I could certainly do her laser ASA but instead I could save her the cost of laser correction and healing and instead max out the toric IOL (SN6AT9, Alcon) and exchanged her toric IOL for the highest toric IOL available. She was extremely pleased with her unaided vision. She did not proceed with planned laser stage as she is very happy with her unaided vision for the first time in her life.

This is an example of maxing out on available technology using the 5S system and also getting personal with the decision to help patients to their end zone once the direction of that end zone was confirmed immediate postoperatively.

In summary, no matter what the cause of a patient's unhappiness after premium cataract surgery, it is in most cases possible to correct both the vision and the relation of the patient in question and their surgeon using a logic-based approach as described in this column.

In the next column, I will address keratoconus as a refractive surgery—thinking outside the cone—a mindset that will revolutionize how surgeons look at and treat one of the most commonly blinding conditions in eye care.

References

Gulani AC. Femtosecond Laser in Refractive Lens Exchange: Surgical Treatment for Presbyopia. Wang M, ed.; Slack Inc., Thorofare, NJ; 2016;109-115.

Gulani AC. Corneoplastique: Art of LASIK & cataract surgery. Ind J Ophthalmol. 2014;62:3-11.

Gulani AC. Evaluating the impact of femto laser-assisted capsulotomy. Cataract Refract Surg Today Europe. 2014;9:36-50.

Gulani AC. Shaping the future and reshaping the past: the art of vision surgery. Chapter 98. In: Copeland and Afshari's Principles and Practice of Cornea. New Delhi, India: Jaypee Brothers Medical Publishers, 2013;2:1252-1273.

March 1, 2016

Donnenfeld E, Gulani AC. Astigmatism correction during cataract surgery. In: Garg H, Alió JL, eds. Femtosecond Laser: Techniques and Technology, 1st ed. Miami, FL: JayPee Highlights Medical Publishers; 2012;21:155-161.