

## AmbioDry™ in the *Times*

### Ophthalmology Times Details Successful Use of AmbioDry for Pterygium Surgery

Pterygium is recognized as one of the oldest ocular pathologies. Multiple and varied approaches and techniques are employed by ophthalmologists throughout the world for the treatment of pterygium. A universally-accepted methodology for successful treatment of this disease has yet to be developed and accepted. The debates continue.

In the September 15th 2003 issue of *Ophthalmology Times*, world-renown Dr. Arun Gulani details his unique, passionate philosophy and surgical approaches to pterygium therapy. The article is powerfully titled:

*Amniotic membrane lowers chance of pterygium recurrence.*


### Amniotic Membrane: A Factor In Recurrence Control

Aggressive pterygium requires aggressive surgery to control recurrence. This is the theme of Dr. Gulani's pterygium philosophy. The availability of amniotic membrane compliments his approach and partners substantially in his low rates of recurrence.

Dr. Gulani: "The basement membrane (of AM) is a type 4 collagen with laminin. The beauty of this structure is that it is similar to the basement membrane of conjunctiva. The advantages of commercially available membrane are that there is no immune reaction... and encourages epithelial

a much wider and extensive area, than that of the visible pterygium, must be removed.

Dr. Gulani: "The part of the pterygium that is visible is only the tip of the iceberg. The most important stage is dissecting the pterygium. The whole plane of the pterygium is delineated subconjunctivally. When it is removed, it resembles a spreading mass of tentacles. It is important to remove the entire mass to avoid recurrence."



### Amniotic Membrane: Doubled-Up Graft Placement

Following excision, Dr. Gulani's placement of the amniotic membrane graft is unique.

Dr. Gulani: "We apply the membrane in a double-folded form, so there is smooth epithelium on both sides, superiorly for epithelialization and below for smooth movement of the underlying extraocular muscle. The central closed portion with the edges positioned medially is then aligned to the limbus."

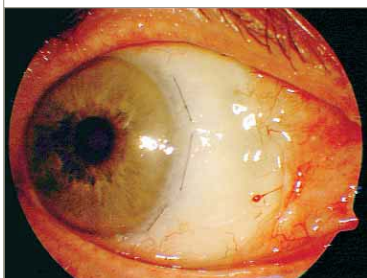
differentiation and growth." Many surgeons, trained and espoused in the use of conjunctival autografts, avoid aggressive excision, fearing inadequate, limited availability of host conjunctiva for defect coverage. The availability of preserved amniotic membrane facilitates and compliments the aggressive excision by providing the surgeon with a plentiful, simple scaffold for epithelialization.

### Complete Excision: Iceberg Concept

The fundamental and critical methodology within Dr. Gulani's surgical approach involves the growth excision. The excision strategy is a product of his Iceberg Concept: it is not the amount of visible pterygium that is the deciding factor for extent of excision. To avoid recurrence,

Arun Gulani, M.D. is the Founding Director of Gulani Vision Institute. OKTO acknowledges the work and expertise of Dr. Gulani and thank him for his contribution to this newsletter.

For more information, Dr. Gulani can be contacted at (904) 296 7393 4500 Salisbury Rd., #160, Jacksonville, Florida - 32216. gulanivision@gulani.com www.gulanivision.com



Dr. Gulani's AmbioDry Patient: Early post-op