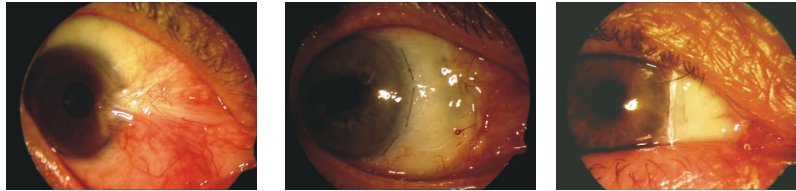

ADVANCED CORNEO-PLASTIC SURGERY: CORNEOPLASTIQUE™ Arun C. Gulani, M.D.

AMNIOTIC MEMBRANE SURGERY-(AMT)

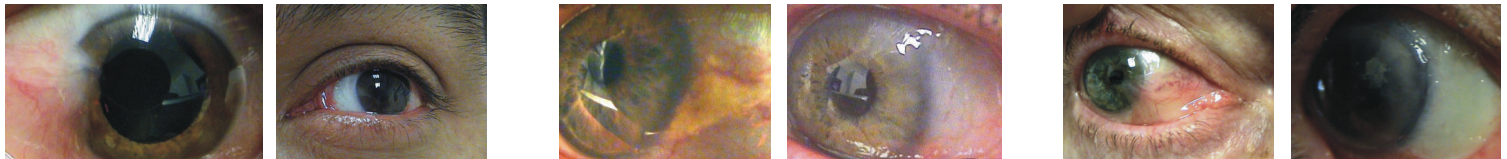
Pterygium / Recurrent Pterygium / Corneal Scars / Conjunctivochalasis / Symblepharon



Nasal Pterygium

Postop Sutured AMT

Postop Glued AMT



Diffuse Pterygium

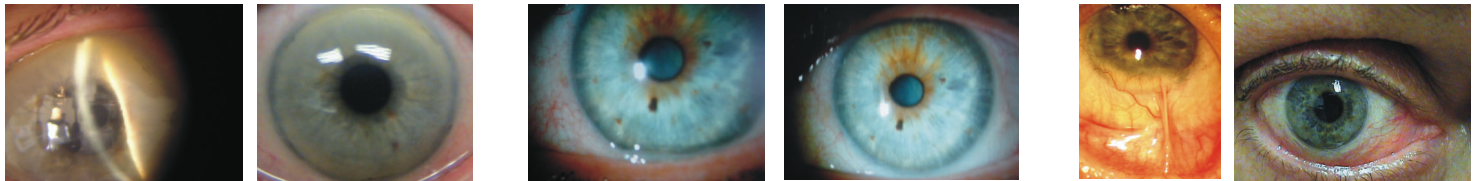
Postop Glued AMT

Lateral Pterygium

Postop
Glued AMT

Reccurent Pterygium

Postop
Glued AMT



Corneal Scar-
PreAmniotic

Corneal Scar Post
AMT

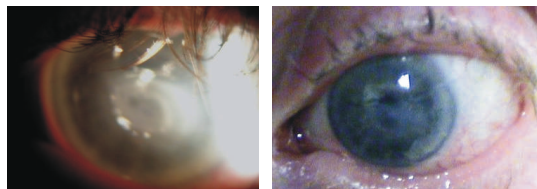
Conjunctivochalasis

Postop
Conjunctivochalasis

Symblepharon

Symblepharon
Postop Glued AMT

Synthetic: Amniotic Membrane in a Contact Lens - PROKERA



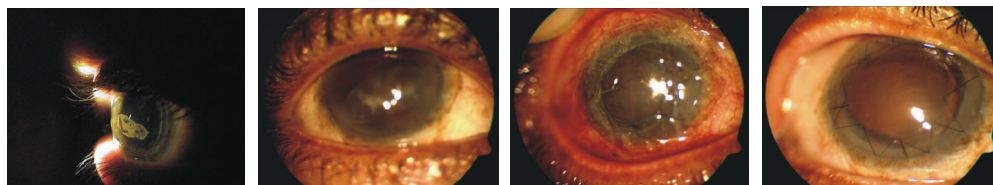
NonHealing Corneal
Defect

Corneal Defect
Healing w/ PROKERA

Kerato-Amnioplasty Surgery

(Combination of Amniotic Graft & Lamellar Cornea)

Band Shaped Keratopathy (BSK)



Band Shaped
Keratopathy

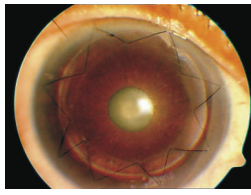
Band Shaped
Keratopathy Preop

KeratoAmnioplasty
1 day Postop

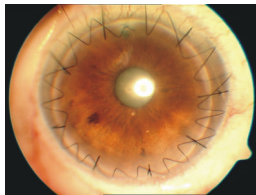KeratoAmnioplasty
1 week Postop

LAMELLAR CORNEAL SURGERY

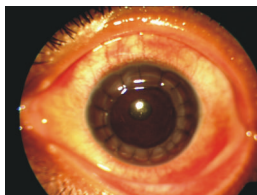Anterior / Deep / Peripheral / Posterior / Penetrating / Epi-Keratophakia Reversal



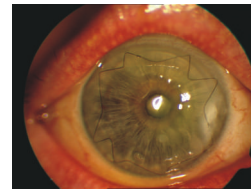
Ant Lamellar Kplasty



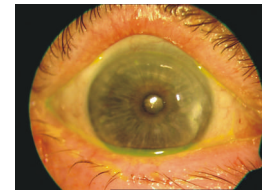
Deep Lamellar Kplasty



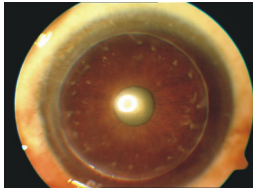
Penetrating Kplasty



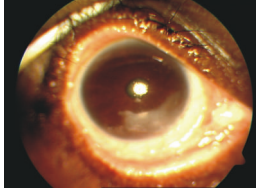
Lasik Flap Melt



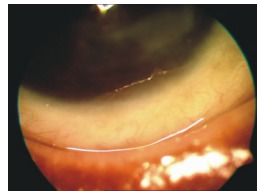
Lasik Flap Melt Post Ant Lamellar Kplasty



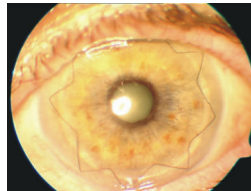Keratoconus Central



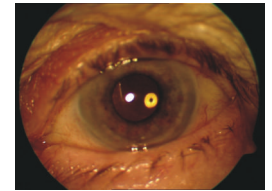
Keratoconus Peripheral Thinning



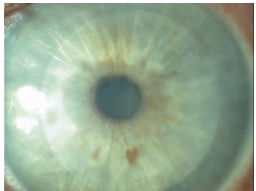
Keratoconus Peripheral Lamellar Keratoplasty



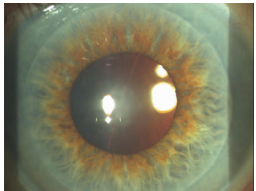
Lamellar KPlasty with Cataract



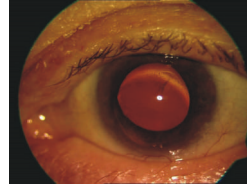Phaco & IOL Post Lamellar KPlasty



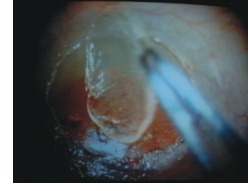
Phakic Posterior Kplasty



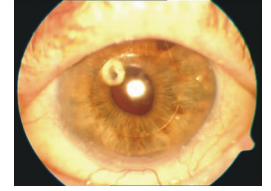
Pseudophakic Posterior Kplasty



Decentered EpiKeratoplasty

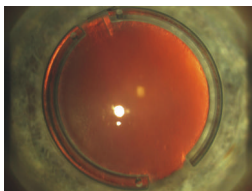


Post Lamellar EpiK Lenticule Removal

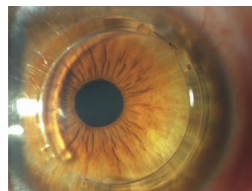


Post EpiK & Sec IOL Vsc 2025

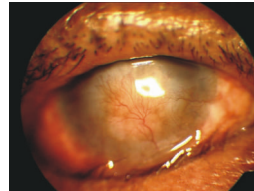Synthetic: INTACS / Artificial Cornea



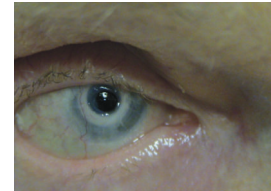
INTACS for Keratoconus



INTACS for Keratoconus



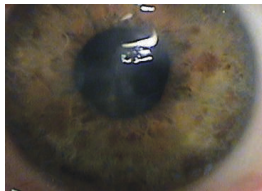
Preop Artificial Cornea



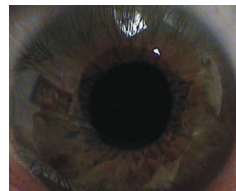
Postop Artificial Cornea

EXCIMER LASER CORNEAL CONTOUR SURGERY

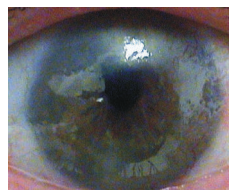
Corneal Scar (Lasik Complications / Infection / Trauma / Previous Refractive Surgery)



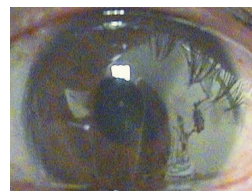Corneal Scar



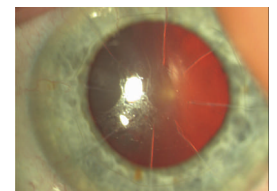
Post Excimer Laser



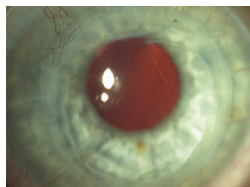
Corneal Scar with Vascularization



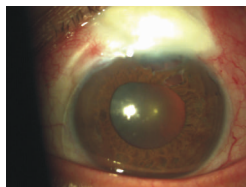Post Excimer Laser



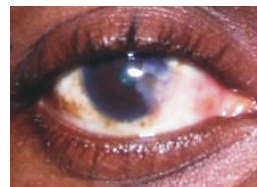
RK Cornea Post Excimer Laser



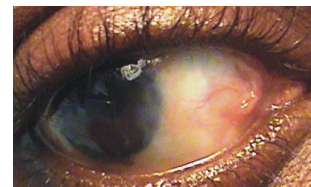
Excimer Laser Post PKP



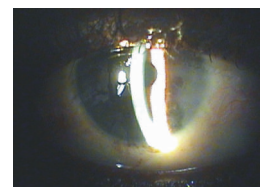
Excimer Laser Post Glaucoma Surgery



Advanced Pterygium Pre-op



One Year Post Glued AMT



Post Excimer Laser Vsc 2020