12

Complex Intraocular Lens Cases

Arun C. Gulani, MD, MS and Tracy Schroeder Swartz, OD, MS, FAAO, Dipl ABO

Unhappy premium intraocular lens (IOL) patients may result from problems with surgical candidacy and dissatisfaction with surgical outcome. Dissatisfaction may occur even when the surgery was performed perfectly. Often, the surgeon did not meet patient expectations, the visual quality is less than acceptable, or the surgeon failed to address the patient's complaints.

Detailed preoperative evaluations are required to ensure there are no contraindications for presbyopia surgery. It is best to identify contraindications prior to surgery, and explain why the patient is not a candidate for the desired lens, rather than addressing a complaint after implantation. Patients with problematic expectations or previous refractive surgery are particularly difficult to satisfy. When evaluating a patient with surgical complications, it may be beneficial to consider a systematic approach, described in Table 12-1. Complications may be related to anatomy, lens-based problems, and patient symptoms and expectations.

Anatomical Complications

Anatomical complications include structural changes to anatomy, such as corneal, iris, or vitreoretinal tissue problems. Ocular inflammation should be corrected prior to surgery, because any ocular surgery can increase both anterior and posterior segment inflammation. Meibomian gland dysfunction, blepharitis, conjunctival chalasis, allergic conjunctivitis, keratoconjunctivitis sicca, vernal conjunctivitis, demodex infection, lagophthalmus, trichiasis, and any other anterior segment abnormalities should be addressed with the patient prior to the procedure. Should these issues increase after surgery, the patient will typically feel the intraocular surgery caused the problem.

Case 1

A 57-year-old male presented following femtosecond laser–assisted cataract surgery with a TECNIS multifocal implant (Johnson & Johnson Vision). He reported his vision had been steadily decreasing in the weeks after surgery, with increasing ocular discomfort. He reported that by the end of the day, his vision left him unable to drive home from work comfortably. Unaided vision was 20/30 OS, and improved to 20/25 with -1.25 +1.50 x 160. The endpoint was soft and varied with blinking. He was unable to discern small changes in refraction. Slit lamp exam revealed significant neovascularization of the lid margins, frothing, and minimal expression (3/15 LL OU) of the meibomian glands. The tear film was thickened, and osmolarity was

Wang M, ed.
Surgical Correction of Presbyopia: The Fifth Wave (pp 111-121).

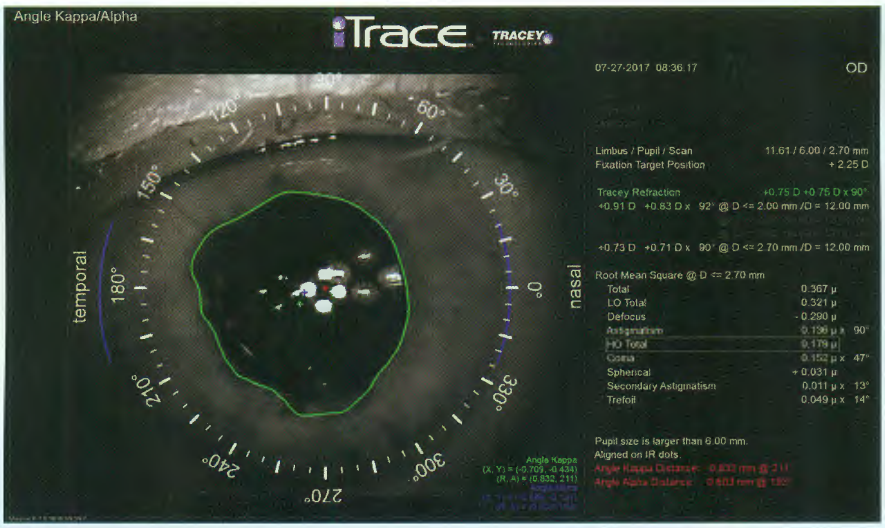

Figure 12-5. Pupil abnormalities, such as an irregular-shaped pupil following the use of iris hooks during cataract surgery can have deleterious effects on vision with a multifocal IOL.

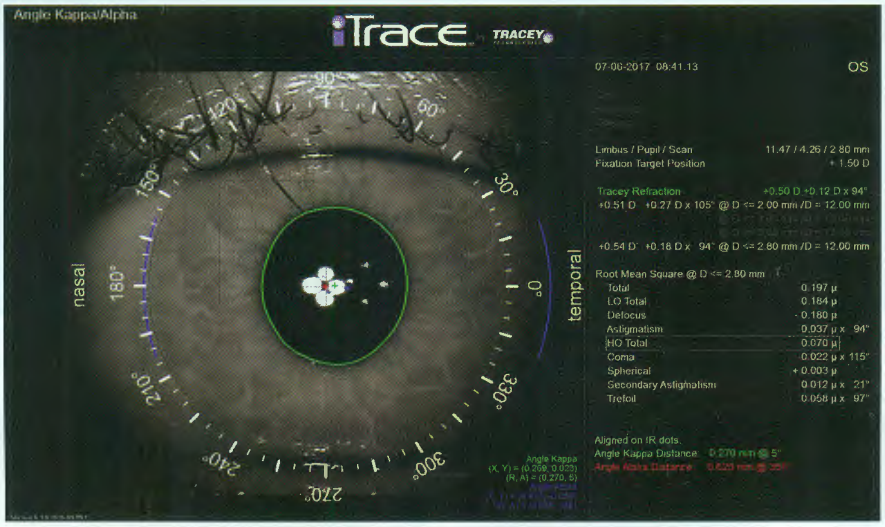

Figure 12-6. Angle kappa is the difference between the visual axis and center of the pupil. Angle alpha is the angle between the visual axis and the center of the limbus. The center of the limbus is thought to predict where the IOL will be positioned after implantation.

In addition to optical alignment, position of the IOL in the bag is related to the capsulorrhexis. A well-centered, properly sized capsulorrhexis is important for multifocal IOL function.[3,4] Decentered capsulotomy may be problematic in multifocal IOL patients if the IOL fails to center in the bag.

Multifocal lenses have a lower threshold for YAG (yttrium-aluminum-garnet) capsulotomy, but must be handled with careful consideration since performing the YAG makes exchange extremely difficult. If the patient was initially happy, and then becomes unhappy with visual function due to posterior capsular haze, the YAG will most likely help. If the patient was never happy with the vision following implantation, YAG may be ill-advised. Capsular haze may alter the refractive error due to fibrosis or distort the vision (Figure 12-7). When performing a YAG, careful application to remove all strands beyond the optical zone and avoid hitting the IOL is recommended.

The posterior segment must also be evaluated in patients with visual complaints. Retinal abnormalities should be identified prior to multifocal implants since reduced macular function will impact the effectiveness of the IOL. Macular optical coherence tomography (OCT) scans are typically performed preoperatively for this reason (Figure 12-8). Three-dimensional, cube analysis is preferred to a macular scan using slices to ensure comprehensive evaluation. Early holes, asymmetric foveal depressions, epiretinal membranes, and slight retinal pigment epithelium disruptions or detachments may be an issue in a 20/20 eye with a multifocal lens.

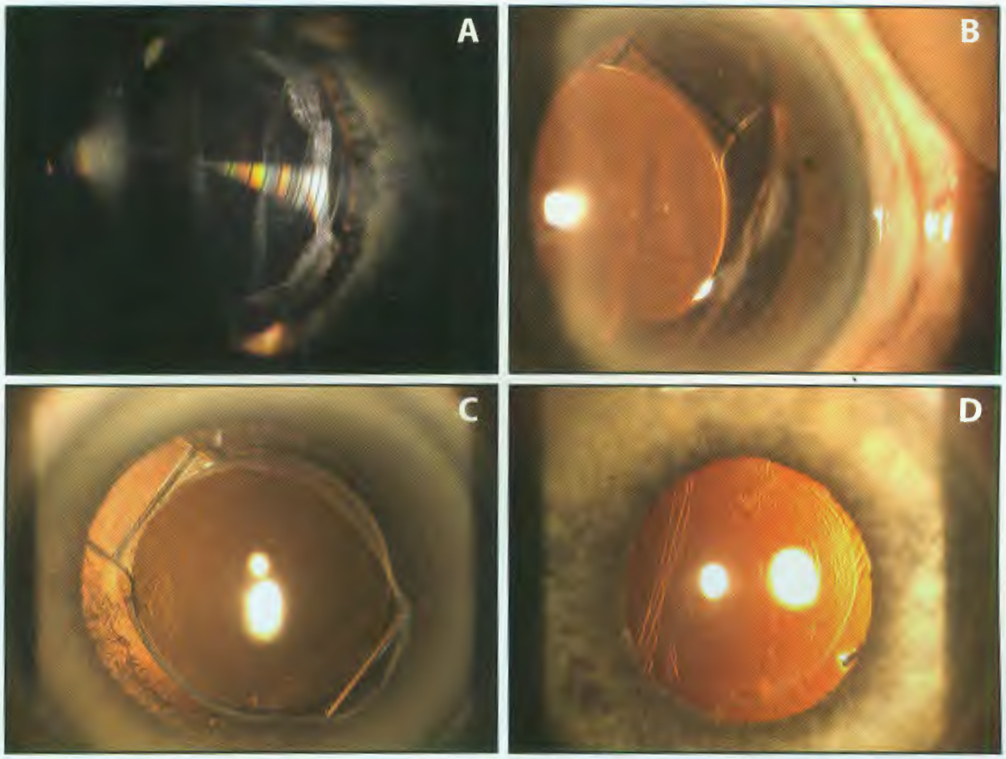

Figure 12-7. (A) A TECNIS Symfony lens 1 day status post-YAG procedure. The strands continue to reduce the vision subjectively. (B) Crystalens (Bausch+Lomb) with a poorly performed YAG. The procedure failed to improve the subjective vision. (C) Crystalens with an improperly performed YAG procedure. (D) Strands on a ReSTOR (Alcon Laboratories, Inc) IOL in a symptomatic patient.

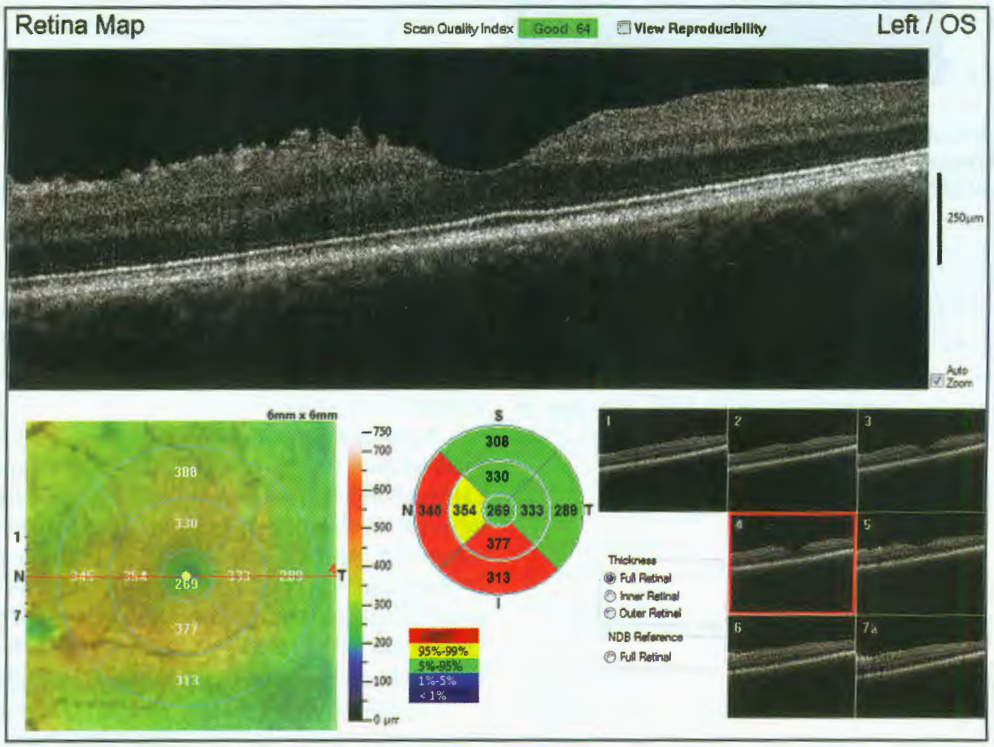

Figure 12-8. An OCT in a 20/20 eye revealed an epiretinal membrane.

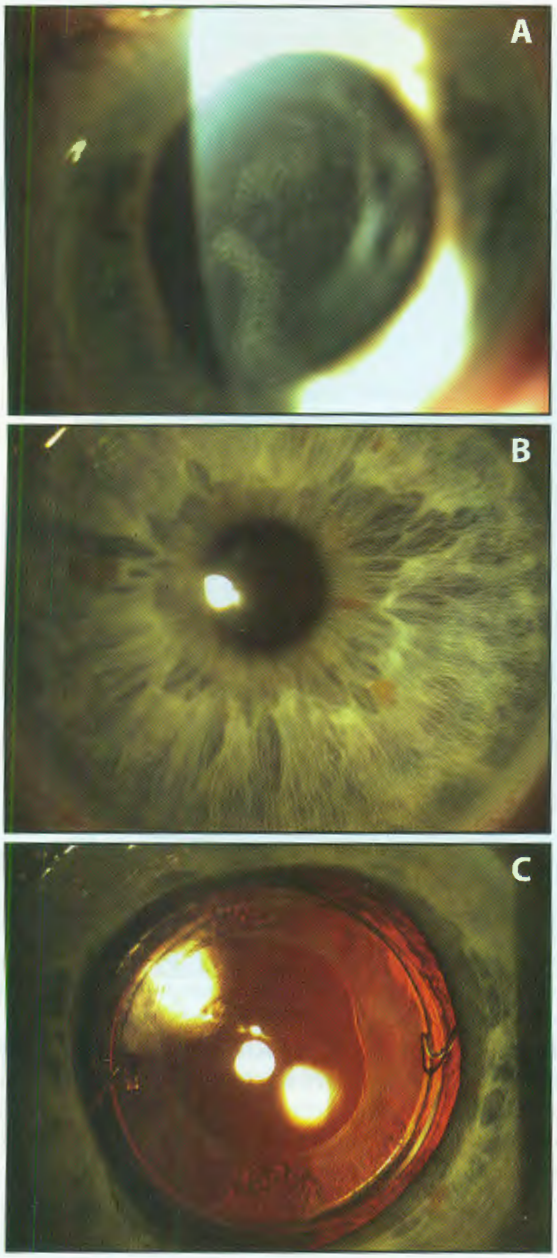

Figure 12-11. (A) Corneal scar resulting from repeated PRK treatments to address residual refractive error. (B) After PRK, 20/25 visual acuity was obtained with significant hyperopia. (C) The residual hyperopia was addressed using a piggyback IOL.

Since the corneal scarring was affecting both visual acuity and corneal measurements required for IOL calculation, the cornea was addressed first. A laser PRK with scar peel to correct the corneal opacity and irregular surface achieved a clear and measurable cornea. Best-corrected vision improved to 20/25 through +6.00 -0.25 x 180. A soft contact lens was worn until the next stage, refractive correction using a piggyback IOL. Due to the YAG capsulotomy, IOL exchange was unadvisable. A piggyback lens implant



Figure 12-12. Multifocal toric IOL.

(STAAR AQ 2010V, +9.0 D) resulted in a 20/20 unaided for distance and J1 (Jaeger) at near with the multifocal IOL in place (Figure 12-11).

Multifocal IOL implantation in patients with a history of keratorefractive surgery is more difficult, but previous keratorefractive surgery is not necessarily a contraindication. Vrijman et al[10] reported 3-month outcomes after ReSTOR multifocal IOLs were implanted in 77 eyes of 43 patients. Eighty-six percent were within ±1.0 D of plano. Sixteen eyes (20.8%) had laser enhancement because of residual refraction, and outcomes were less predictable in those with preoperative refractive error greater than -6.0 D.[10]

LASIK, PRK, RK, and lamellar keratoplasty may increase higher order aberrations, in some cases resulting in multifocality. This results in a decrease in contrast, particularly for larger pupil sizes. Implanting a multifocal IOL with a multifocal cornea may cause an additional loss of contrast and overall reduction in visual quality.[11] Careful examination of the corneal topography is essential in these patients. Implantation of a toric IOL in a patient with central astigmatism can be challenging (Figure 12-12).

Case 6

A 67-year-old male presented with a history of RK years ago, followed by cataract surgery with a TECNIS Symfony IOL 4 months prior. Refraction revealed +0.25 -2.00 x 130 (20/60) with significant shadowing of letters. Dilated fundus exam revealed the implant was decentered superiorly relative to the pupil. Topography revealed a small, inferiorly decentered optical zone with increased corneal coma with a severe inferior-superior value (-10.95 D), spherical aberration (+0.895 μm). The corneal optic zone was inferior, while the IOL optic center was superior, resulting in diplopia.

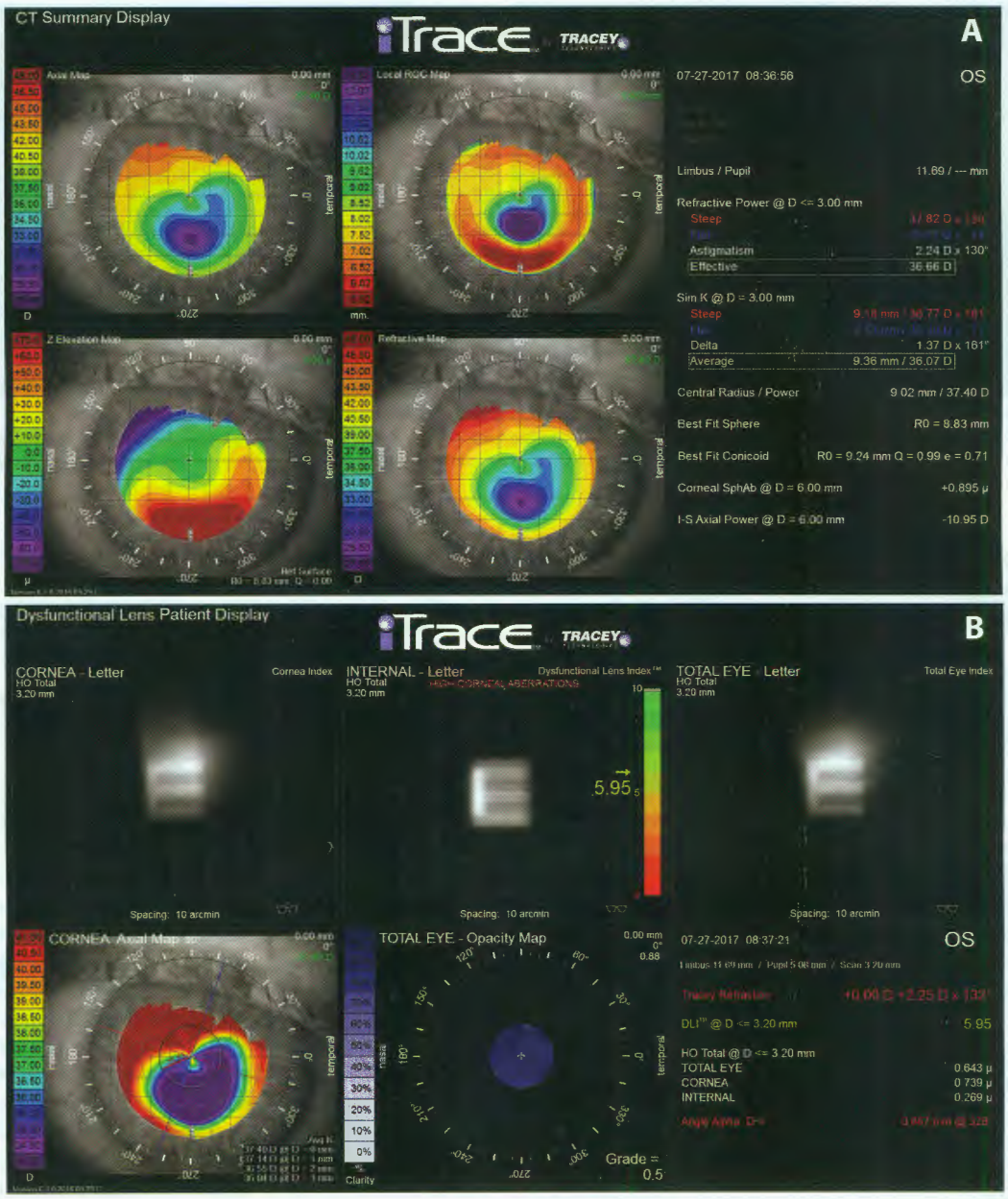

Figure 12-13. (A) Corneal topography of an RK patient. Note the difference in refractive and simulated keratometry readings, and large inferior-superior value. This patient was not a good candidate for a TECNIS Symfony IOL. (B) The decentration pictured in the axial map (lower left) manifests as distortion, particularly coma (upper left). The displacement of the TECNIS Symfony IOL superiorly results in the shadows on the internal Snellen E (upper middle). The whole eye E (upper right) and corneal E are nearly identical, suggesting the visual performance issues are linked to the cornea, rather than the TECNIS Symfony IOL.

Angle alpha was 0.667, far too high for comfortable vision with a premium lens. The lens was exchanged for a monofocal IOL. The patient reported vision appeared brighter and less blurred the day after surgery. At 1 month, the patient was able to see 20/30 with +0.75 -1.50 x 135 (Figure 12-13).

Most corneal irregularities, opacities, and residual refractive errors can be successfully addressed using corneal surgery. Phototherapeutic keratectomy and deep anterior lamellar keratoplasty can correct opacities. Topography-guided advanced surface ablation will correct irregular astigmatism. Fuchs' dystrophy is corrected using Descemet stripping automated endothelial keratoplasty (DSAEK). While these are best performed preoperatively, they are successful after multifocal IOL implantation.

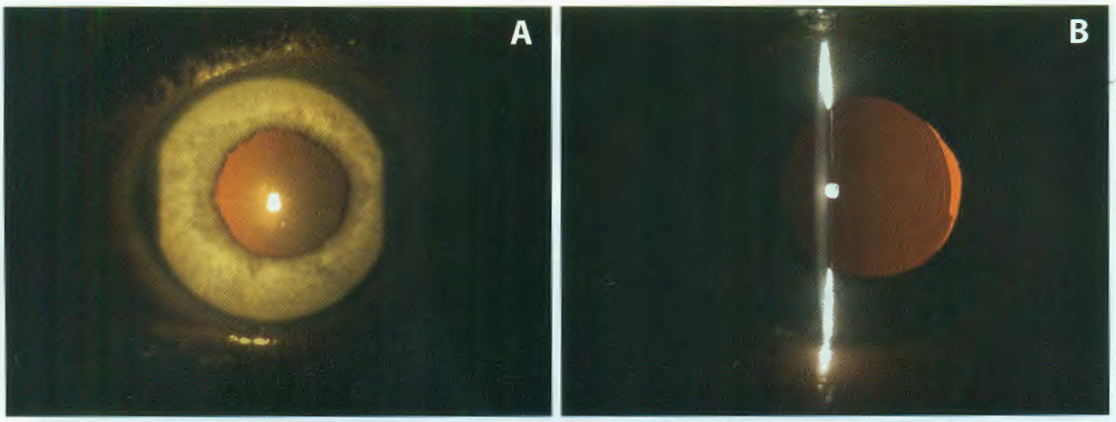

Figure 12-14. (A) This patient was 20/20 best-corrected vision after ReSTOR followed by PRK for residual refractive error. The patient sought a second opinion for corrective surgery. The vision loss was due to corneal scarring and irregular astigmatism. (B) A scar peel was successful in removing corneal haze. The patient was satisfied with the resultant vision and elected to forego further surface ablation.

In some cases, residual refractive error and patient dissatisfaction may require explantation. Explantation may be performed when demanded by the patient, especially when the visual complaints began immediately after implantation. This suggests the implant is the culprit of the complaint. If the visual complaint was not apparent immediately after surgery, posterior capsular opacification, ocular surface disease, or retinal changes must be ruled out. Indications for IOL explantation include spontaneous IOL in-the-bag dislocations, incorrect lens power, or failure to neuroadapt to multifocal IOLs.[12] Various lenses may be safely used for exchange following a multifocal IOL implantation, including in-the-bag IOLs, iris-sutured IOLs, sulcus-fixated IOLs with optic capture, sulcus-fixated IOLs without optic capture, and anterior chamber IOLs.[13] Note that explanting a lens is rarely performed after a YAG procedure.

Patient Symptomatology and Dissatisfaction

In some cases, patients may not have been adequately educated about and prepared for the visual side effects of presbyopic treatments. While the surgeon may deem the surgery to be perfect, the patient feels burdened by halos, glare, inability to read small print, and loss of distance vision. Realistic expectations are paramount to avoid not meeting patients' goals post surgery. Some patients can be negatively or psychologically affected or unprepared for improper or unexpected endpoints such as glare and halos. Demonstration of the correction of refractive error may be performed using contact lenses to determine if the visual symptoms resolve with correction and reassure the patient. They may find relief only with exchange of the IOLs.

Case 7

This patient had undergone a diffractive multifocal +23.0 D SN6AD1 ReSTOR lens implant and was unhappy with her quality of vision. Initial evaluation revealed unaided 20/40 vision with significant ocular surface disease that was corrected with meibomian gland probing and lacrimal plugs. After improving her dry eye, her manifest refraction stabilized to -0.25 -0.50 x 065 (20/20). Simulated demonstration of the refractive error improved her subjective complaint. She proceeded with a surface ablation. Her final outcome was 20/20 unaided with plano refraction (Figure 12-14).

Despite her improved vision following the laser vision surgery, she returned because she was still angry at her previous surgeon for not explaining the halos and glare that could occur with this lens implant. After extensive discussions on multiple occasions with her and her husband in attendance, she understood her vision had improved and that she no longer suffered symptoms she had read about online. Despite the improvement, she felt it was agonizing for her to live with something that could cause symptoms, and this was resulting in significant mental anguish. Risk of a lens exchange in a 20/20 eye was exhaustively discussed, and an informed consent was created specifically for this procedure. Her multifocal lens was exchanged with a +23.50 SN60WF ReSTOR monofocal lens implant. She was 20/25 unaided the next day and 20/20 unaided 1 week later. She was much more comfortable with this lens choice.

Case 8

This patient suffered a traumatic, subluxated cataract with dilated pupil, and was referred for pupil repair and cataract surgery. We discussed her options, and she elected to avoid pupilloplasty. We realized her dilated eye was the nondominant eye, and discussed myopia for monovision. This would result in blur in this eye for distance with

Figure 12-15. This patient was referred after trauma resulted in permanent mydriasis and subluxated cataractous lens. Knowing the zonules might be affected, a multifocal IOL is not advisable. She was motivated for both distance and near correction, however, complicating the case. The patient preferred to avoid pupilloplasty. The dilated, nondominant eye was operated on first, with a myopic endpoint to allow her functional vision at near while masking the dilated pupil effect upon distance acuity. The dominant eye was 20/20 at distance after a toric IOL was implanted.

Figure 12-16. A toric IOL was implanted in an RK patient who suffered from corneal decompensation and vision loss. A modified DSAEK with thin graft, focused centration, and secure incision enabled her to regain her vision back without disturbing the IOL.

minimal pupil induced visual impact, while the dominant eye (with normal pupil) would be corrected to 20/20 unaided vision. The near and less predictable eye was done first. The second eye's outcome becomes more predictable given the results of the first, allowing the surgeon to fine tune IOL calculations. This patient resulted in 20/20 at distance and near without glasses and was very pleased with her vision despite forgoing the pupilloplasty (Figure 12-15).

Case 9

This patient sought a second opinion after endothelial failure and corneal decompensation following cataract surgery with a premium toric implant in a cornea with multiple RK incisions. Prior to corneal decompensation, the vision had been quite good. Leaving the IOL in place, modified DSAEK was performed. Due to the astigmatism in the IOL, sutures should be avoided. Surgery should be as nonintrusive as possible with thin graft, focused centration, and secure incision (Figure 12-16).

Complications with multifocal IOLs are more common than with monofocal IOLs. Many examples here show proper presurgical work-up is essential to success, as well an understanding of the optics involved. The increased demand for spectacle independence also increases the risk of patient dissatisfaction.

Acknowledgment

Ms. Aaishwariya A. Gulani, (Wharton School of Business, University of Pennsylvania) for compilation of cases.

References

1. de Vries NE, Webers CA, Touwslager WR, et al. Dissatisfaction after implantation of multifocal intraocular lenses. *J Cataract Refract Surg.* 2011;37(5):859-865.
2. Park CY, Oh SY, Chuck RS. Measurement of angle kappa and centration in refractive surgery. *Curr Opin Ophthalmol.* 2012;23(4):269-275.
3. Davison JA. Analysis of capsular bag defects and intraocular lens positions for consistent centration. *J Cataract Refract Surg.* 1986;12(2):124-129.
4. Oner FH, Durak I, Soylev M, Ergin M. Long-term results of various anterior capsulotomies and radial tears on intraocular lens centration. *Ophthalmic Surg Lasers.* 2001;32(2):118-123.
5. Pepose JS. Maximizing satisfaction with presbyopia-correcting intraocular lenses: the missing links. *Am J Ophthalmol.* 2008;146(5):641-648.
6. Alio JL, Abdelghany AA, Fernández-Buenaga R. Enhancements after cataract surgery. *Curr Opin Ophthalmol.* 2015;26(1):50-55.
7. Gundersen KG, Makari S, Ostenstad S, Potvin R. Retreatments after multifocal intraocular lens implantation: an analysis. *Clin Ophthalmol.* 2016;10:365-371.
8. Chen YT, Tseng SH, Ma MC, Huang FC. Corneal epithelial damage during LASIK: a review of 1873 eyes. *J Refract Surg.* 2007;23(9):916-923.
9. López-Montemayor P, Valdez-García JE, Loya-García D, Hernandez-Camarena JC. Safety, efficacy and refractive outcomes of LASIK surgery in patients aged 65 or older. *Int Ophthalmol.* 2017 Jun 23. doi: 10.1007/s10792-017-0614-3.
10. Vrijman V, van der Linden JW, van der Meulen IJE, Mourits MP, Lapid-Gortzak R. Multifocal intraocular lens implantation after previous corneal refractive laser surgery for myopia. *J Cataract Refract Surg.* 2017;43(7):909-914. doi: 10.1016/j.jcrs.2017.06.028.
11. Braga-Mele R, Chang D, Dewey S, et al; ASCRS Cataract Clinical Committee. Multifocal intraocular lenses: relative indications and contraindications for implantation. *J Cataract Refract Surg.* 2014;40(2):313-322.
12. Fernández-Buenaga R, Alio JL. Intraocular lens explantation after cataract surgery: indications, results, and explantation techniques. *Asia Pac J Ophthalmol (Phila).* 2017;6(4):372-380. doi: 10.22608/APO.2017181.
13. Kim EJ, Sajjad A, Montes de Oca I, et al. Refractive outcomes after multifocal intraocular lens exchange. *J Cataract Refract Surg.* 2017;43(6):761-766. doi: 10.1016/j.jcrs.2017.03.034.